



*Disclosure belangen spreker*

(potentiële) belangenverstrengeling	Geen
Voor bijeenkomst mogelijk relevante relaties met bedrijven	Geen
<ul style="list-style-type: none"><li>• Sponsoring of onderzoeksgeld</li><li>• Honorarium of andere (financiële) vergoeding</li><li>• Aandeelhouder</li><li>• Andere relatie, namelijk ...</li></ul>	<ul style="list-style-type: none"><li>•</li><li>•</li><li>•</li><li>•</li></ul>

*Symposium “Het proctum”*

*Theater de Veste, Delft, 21 januari 2014*

*MRI van het (kleine) bekken:  
perianale fistels*

*Frank Zijta, radioloog*

*MCH*

*Den Haag*

# *Perianal fistulas*

- *Prevalence approximately 0.01%*
- *Cryptoglandular (90%)*
  - *Infection intersphincteric anal glands, leading to an abscess*
- *Predominantly young adults*
- *Male:female ratio 2:1*

# *Perianal fistulas in Crohn disease (CD)*

- *Crohn's disease 40% perianal fistulas*
- *Up to 36% CD present with a perianal fistula as initial complaint*
- *In CD often more complex disease*

Hellers et al. Gut 1980;21:525–527.

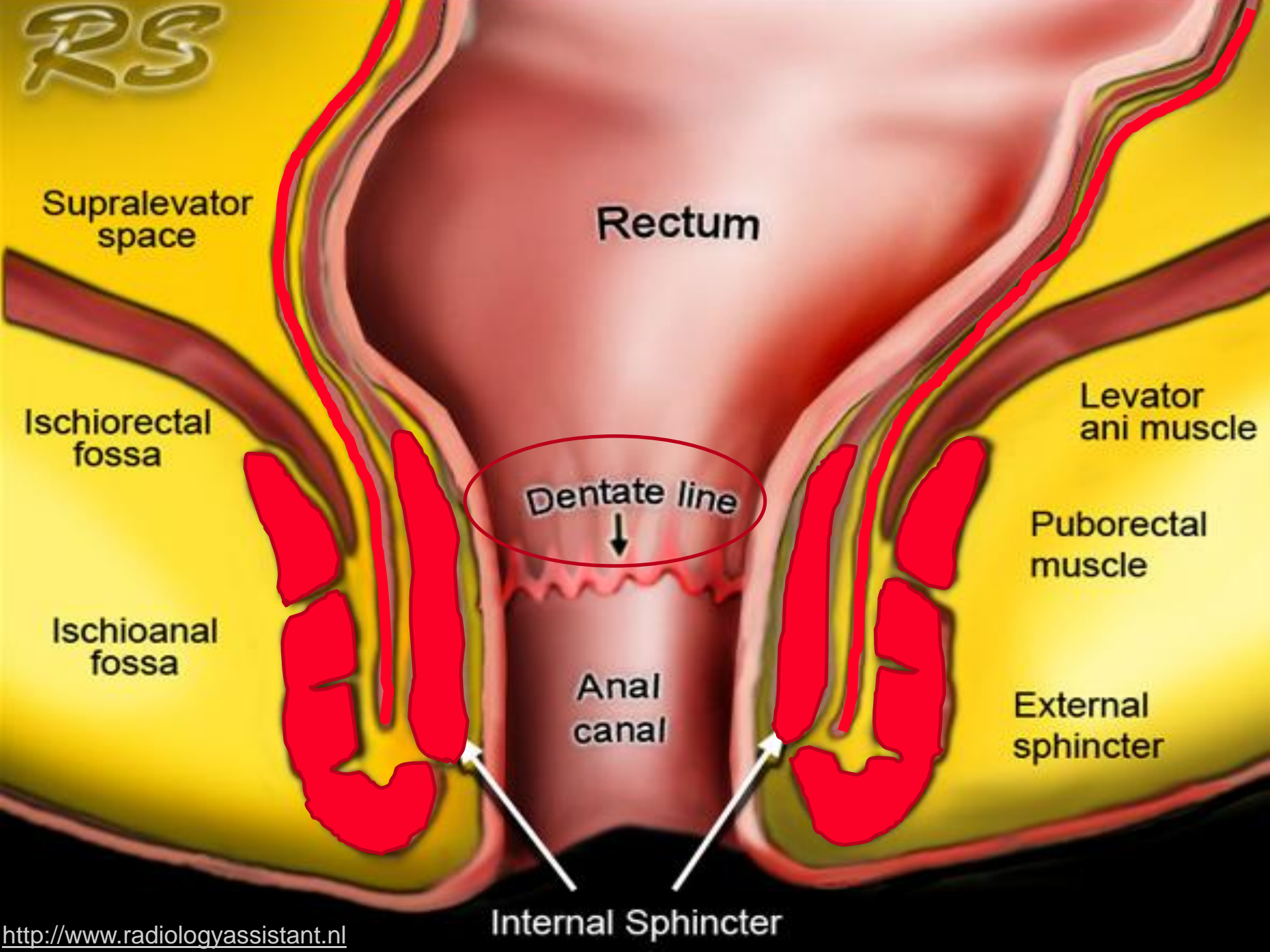
Schwartz et al. Gastroenterology 2002;122:875–880

Williams et al. Dis Colon Rectum 1981;24:22–24

Fields et al. Inflamm Bowel Dis 2008;14:29–31

# *Anal Anatomy*

RS



Supralelevator space

Rectum

Ischioanal fossa

Levator ani muscle

Dentate line

Puborectal muscle

Ischioanal fossa

Anal canal

External sphincter

Internal Sphincter

# *MRI Coils*



# *Technical aspects*

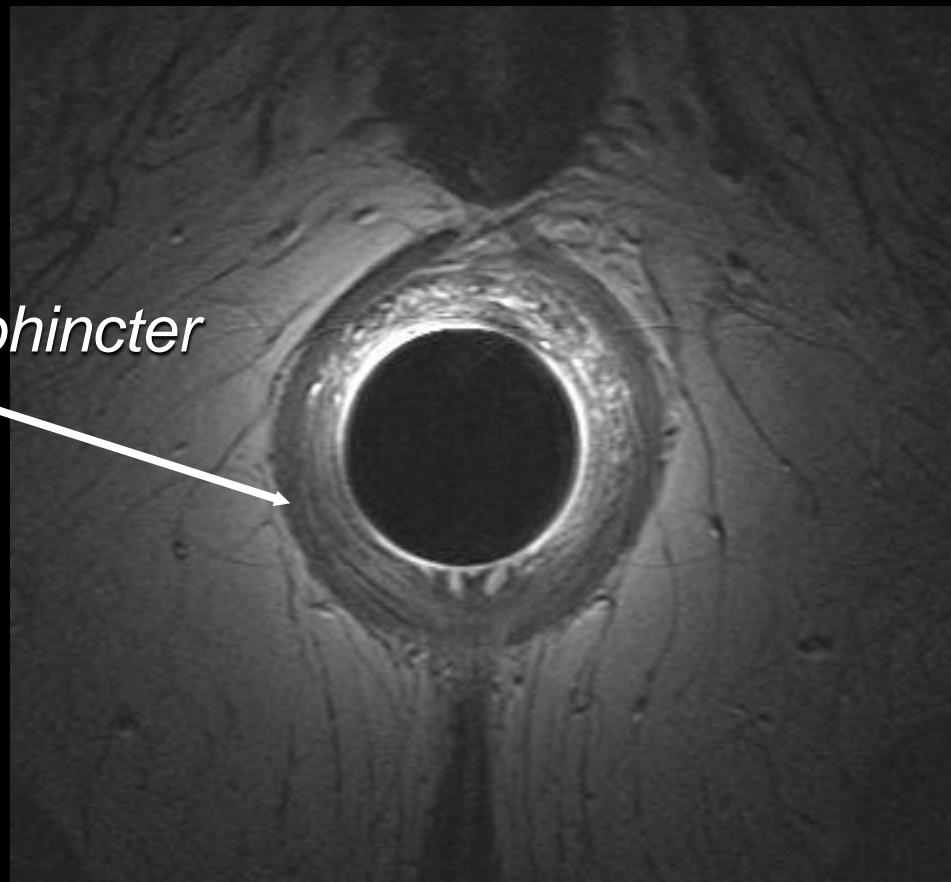
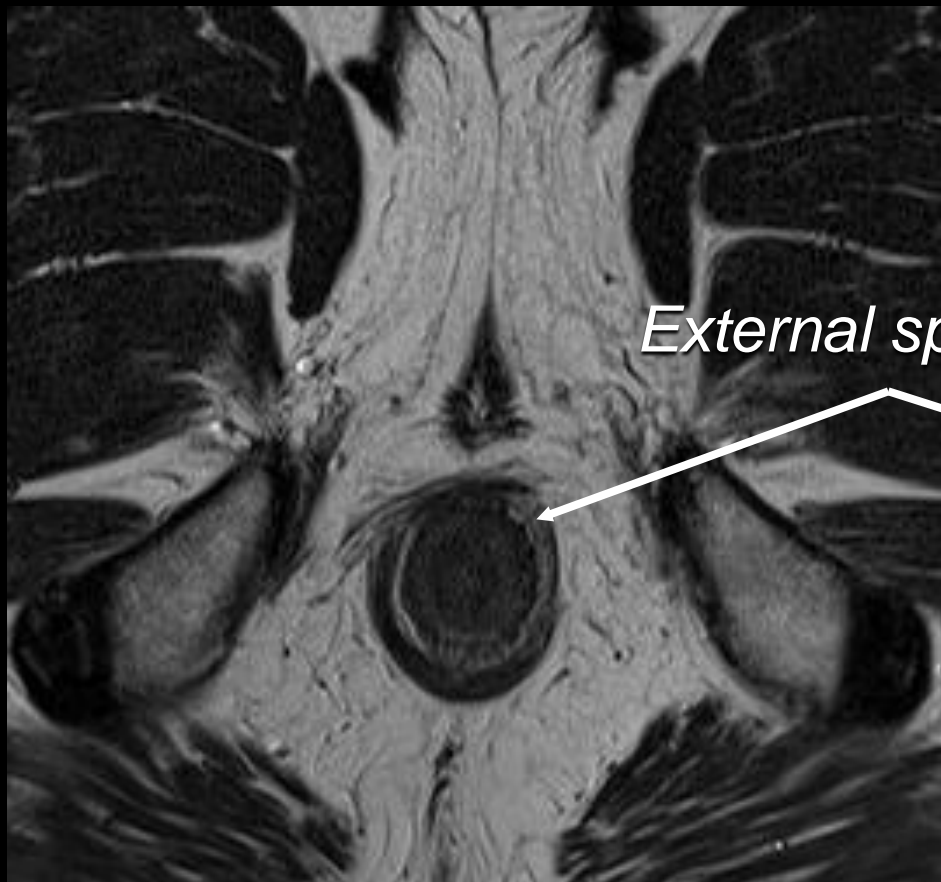
- *External coil*
- *Endoanal coil:*
  - *Internal opening (cryptoglandular)*
  - *Anovaginal fistula*



# *Anatomical Landmarks*

*External coil, male*

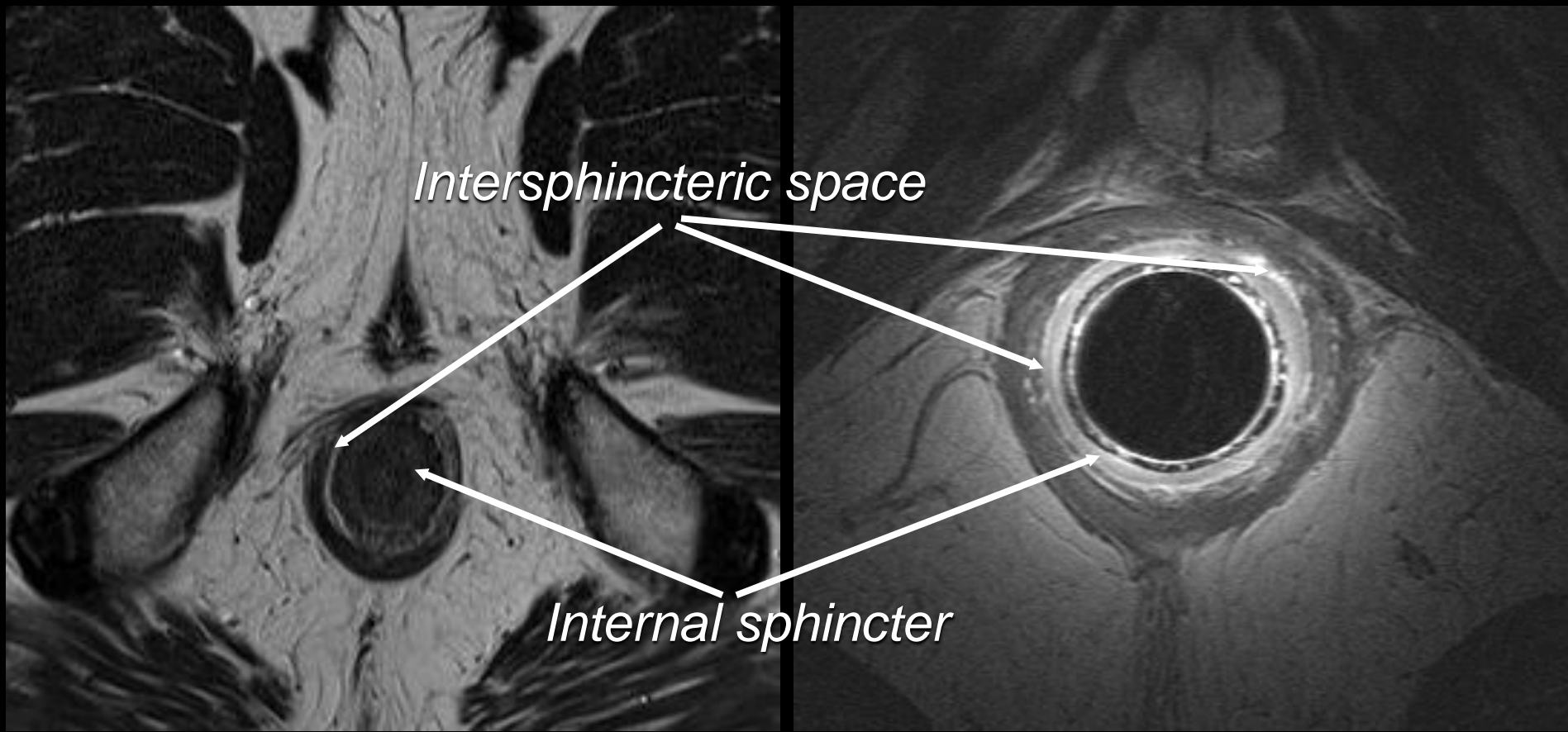
*Internal coil, male*



*External sphincter*

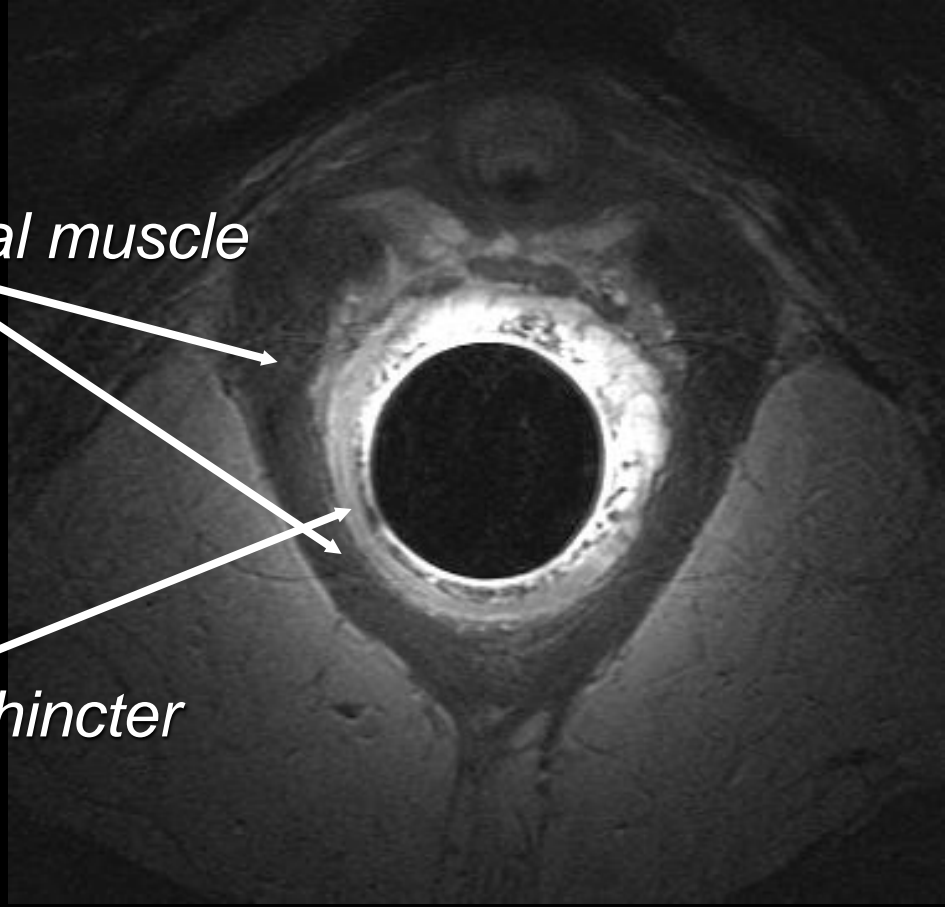
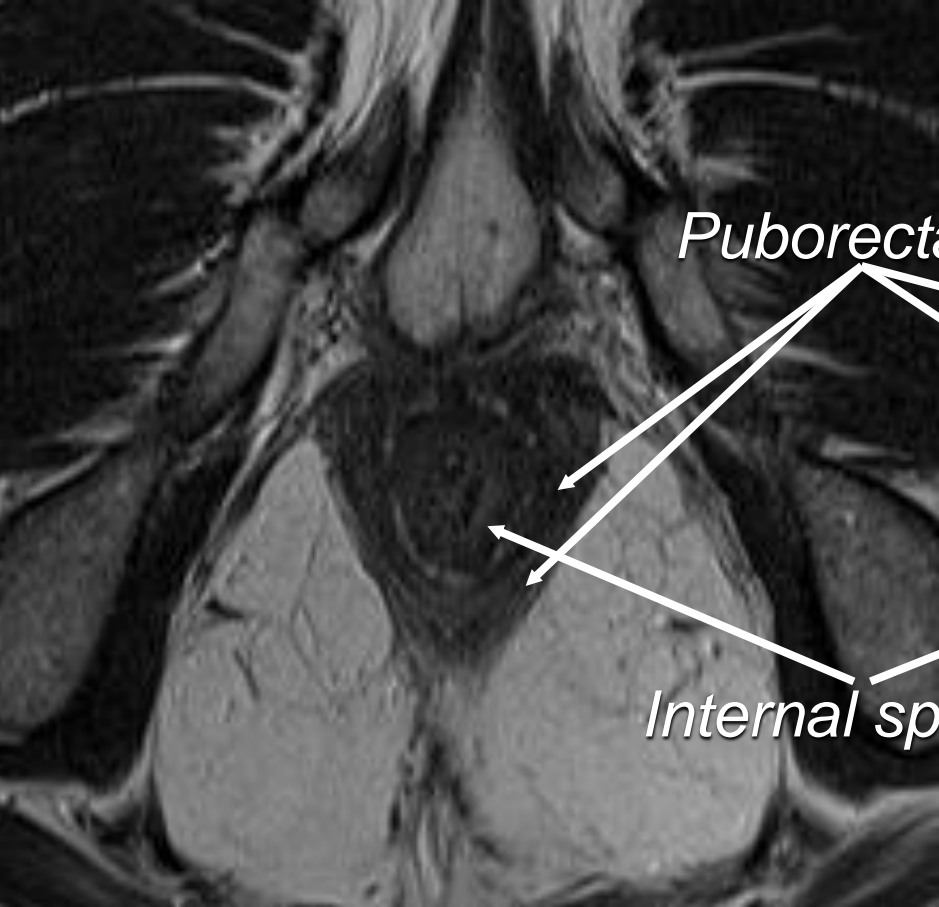
*External coil, male*

*Internal coil, male*



*External coil, male*

*Internal coil, male*

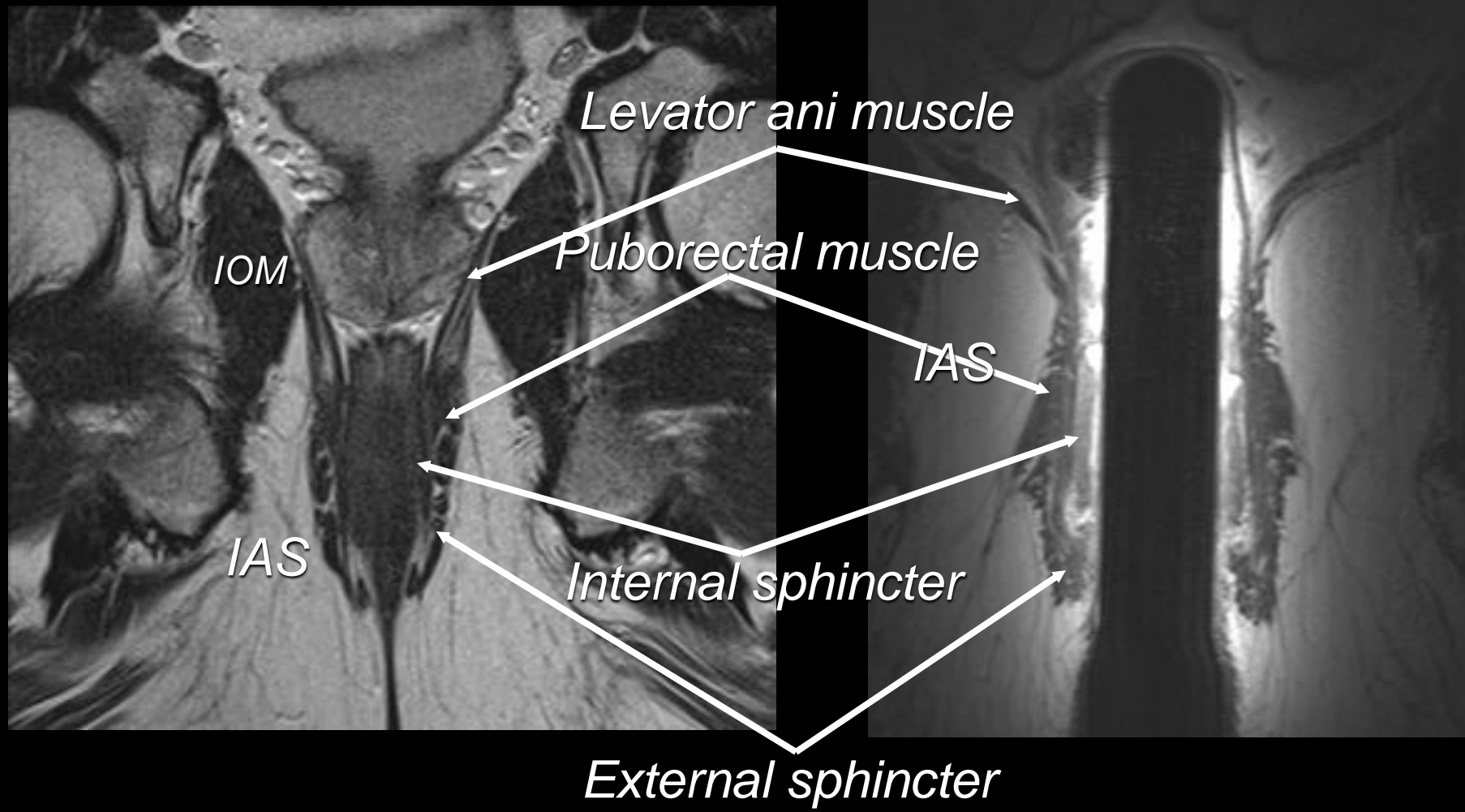


*Puborectal muscle*

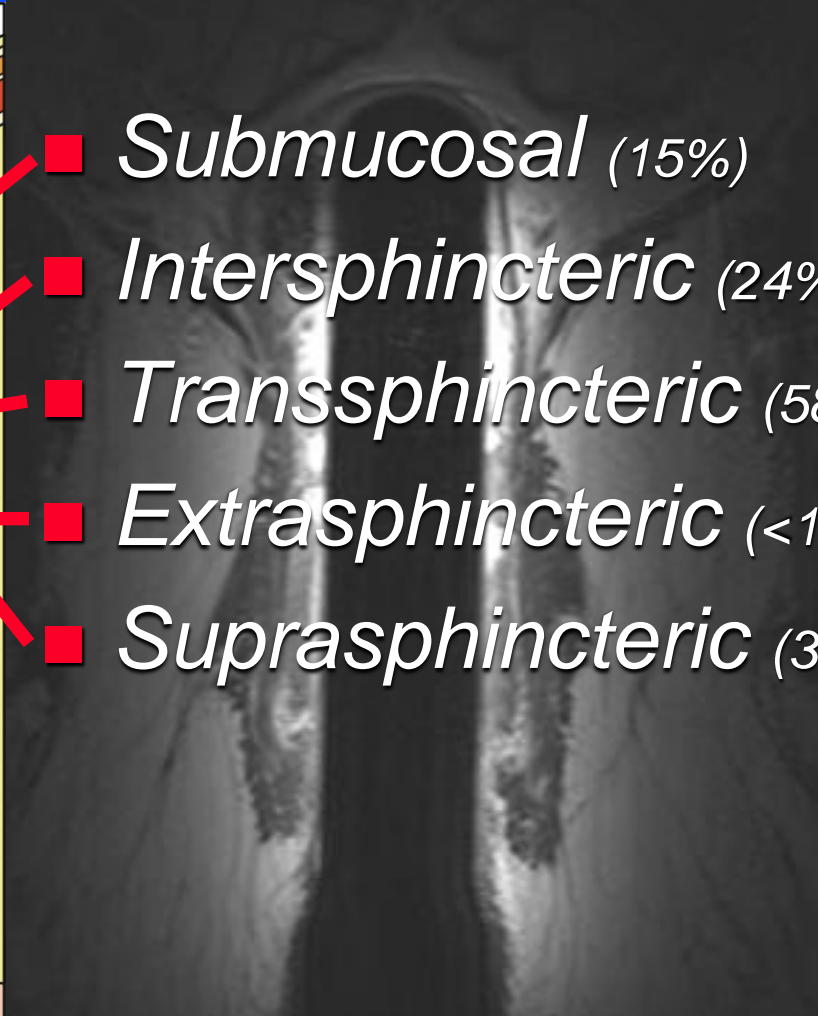
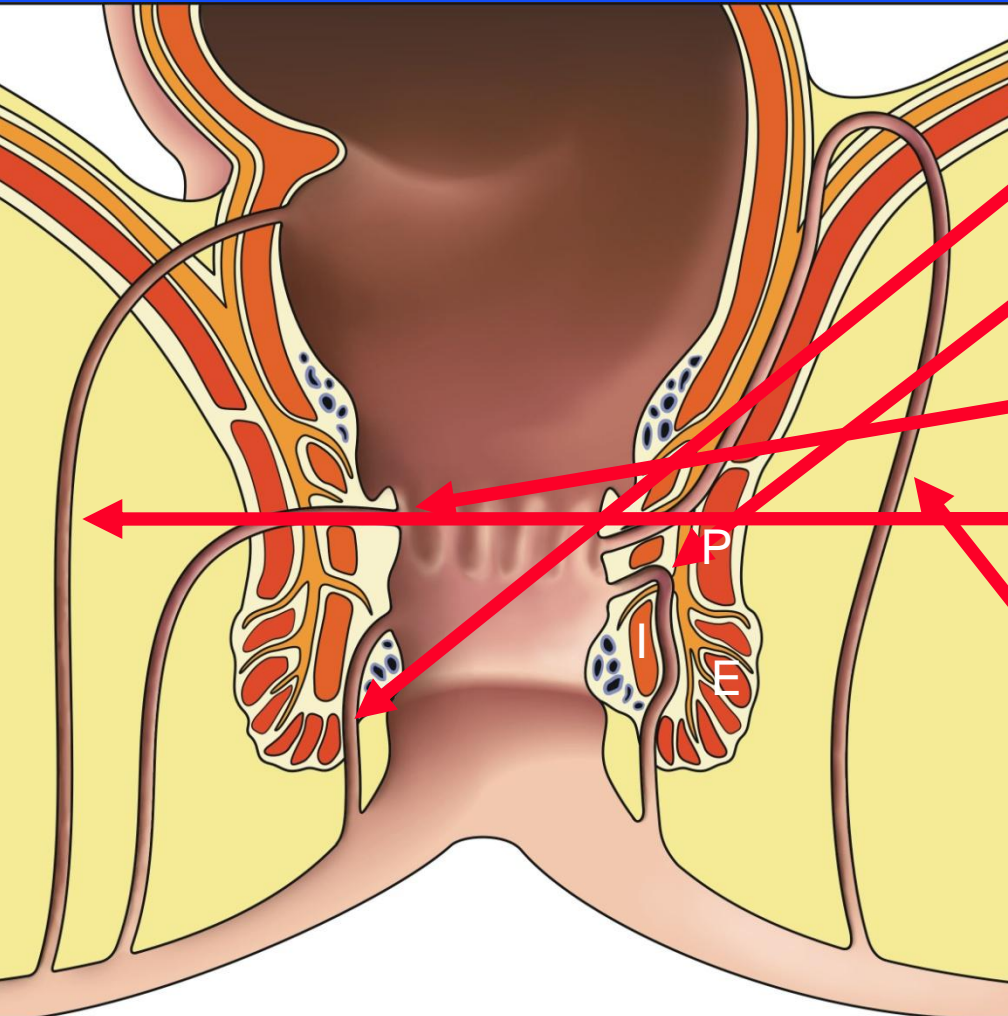
*Internal sphincter*

*External coil, male*

*Internal coil, male*



# *Classification*



- *Submucosal* (15%)
- *Intersphincteric* (24%)
- *Transsphincteric* (58%)
- *Extrasphincteric* (<1%)
- *Suprasphincteric* (3%)

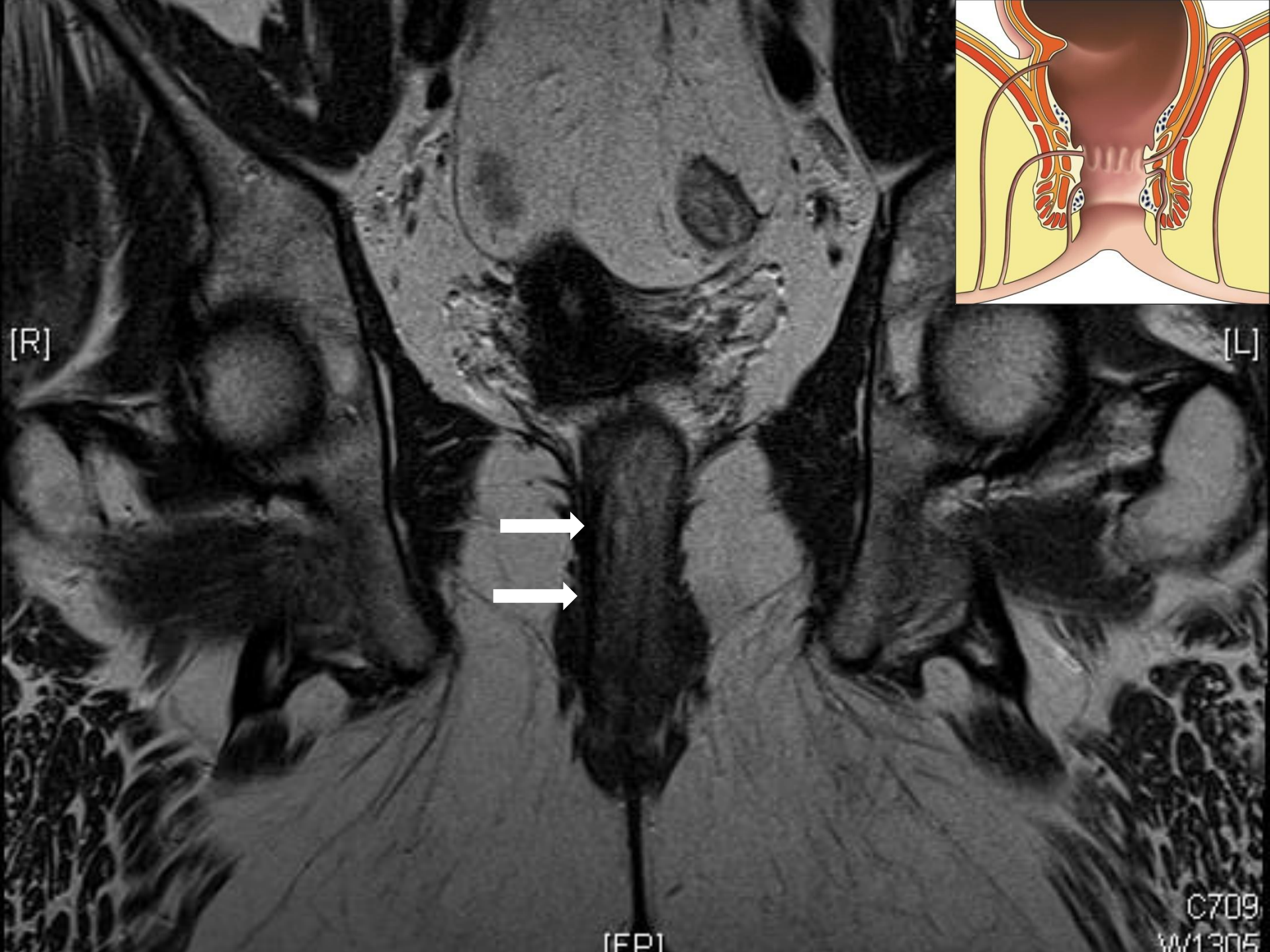Horsthuis and Stoker. AJR 2004; 183:1309-1315  
Halligan and Stoker. Radiology 2006;239:18-33  
Rosa et al. Tech Coloproctol 2006;10:215-221

# *Assessment*

- *What is the relationship between the fistula and the anal sphincter*
- *Extensions from the primary tract?*




# *Case 1*



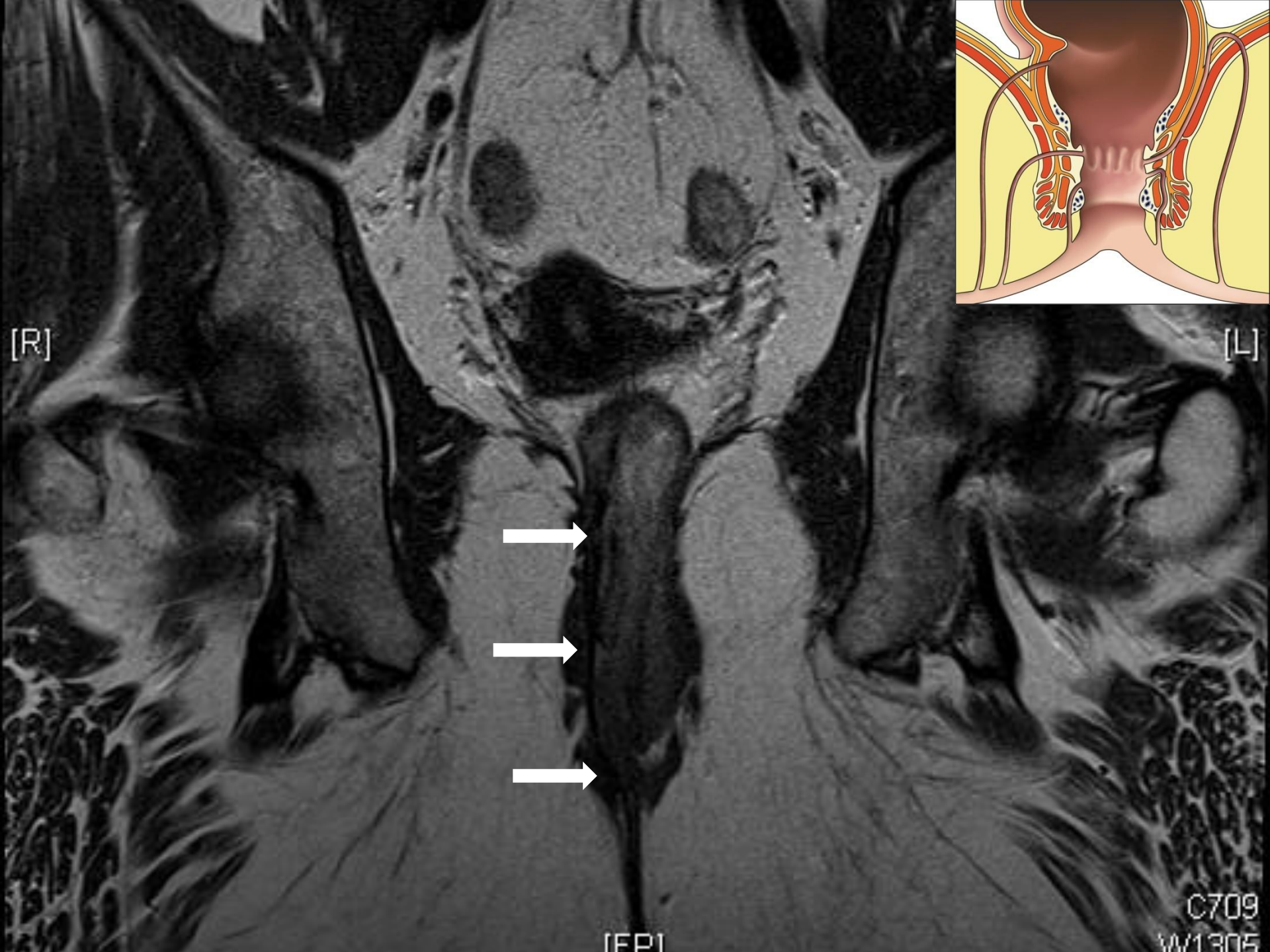[R]

[L]



[FPI]

C709  
W1305



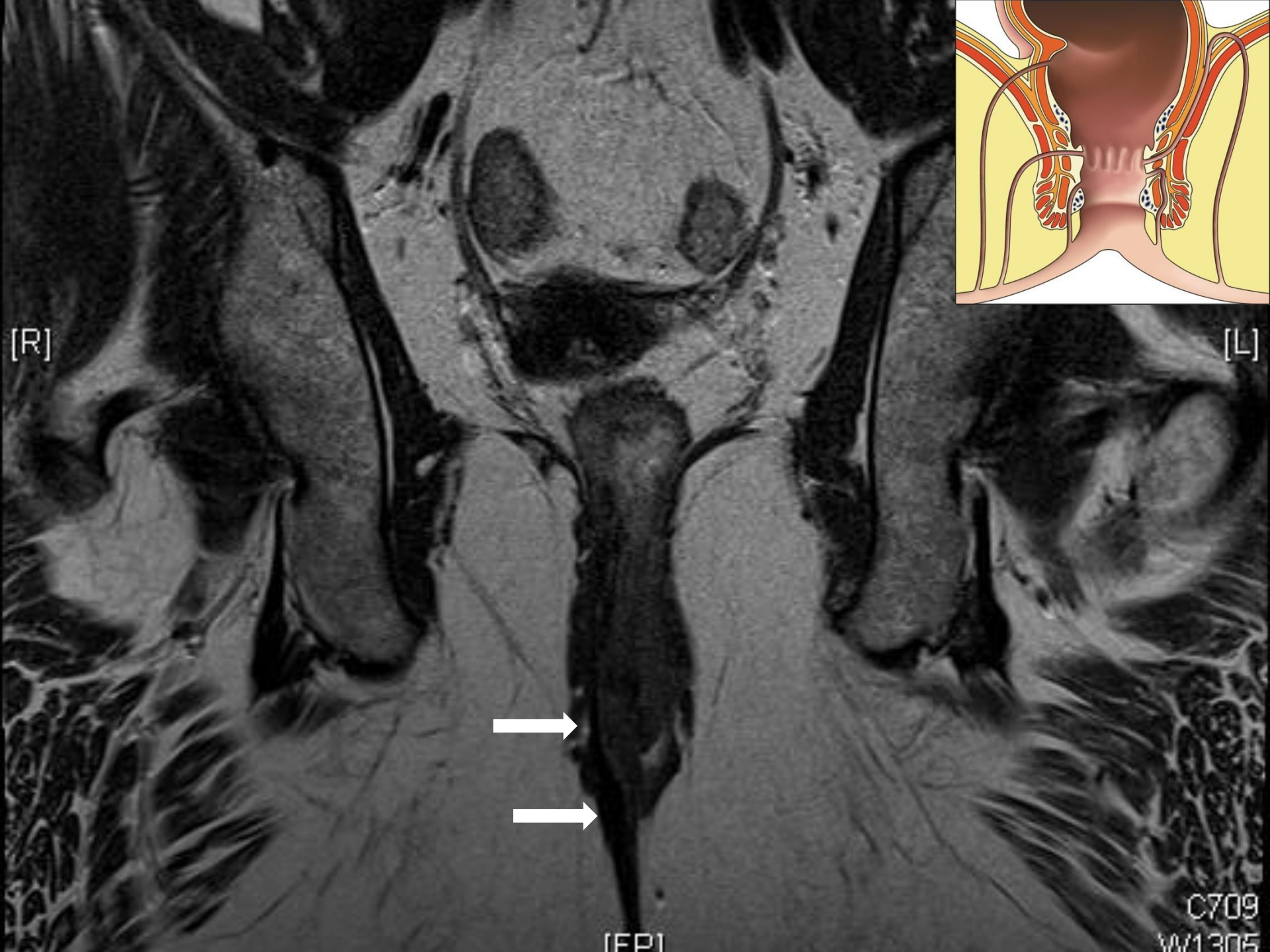[R]

[L]




[FPI]

C709  
W1305



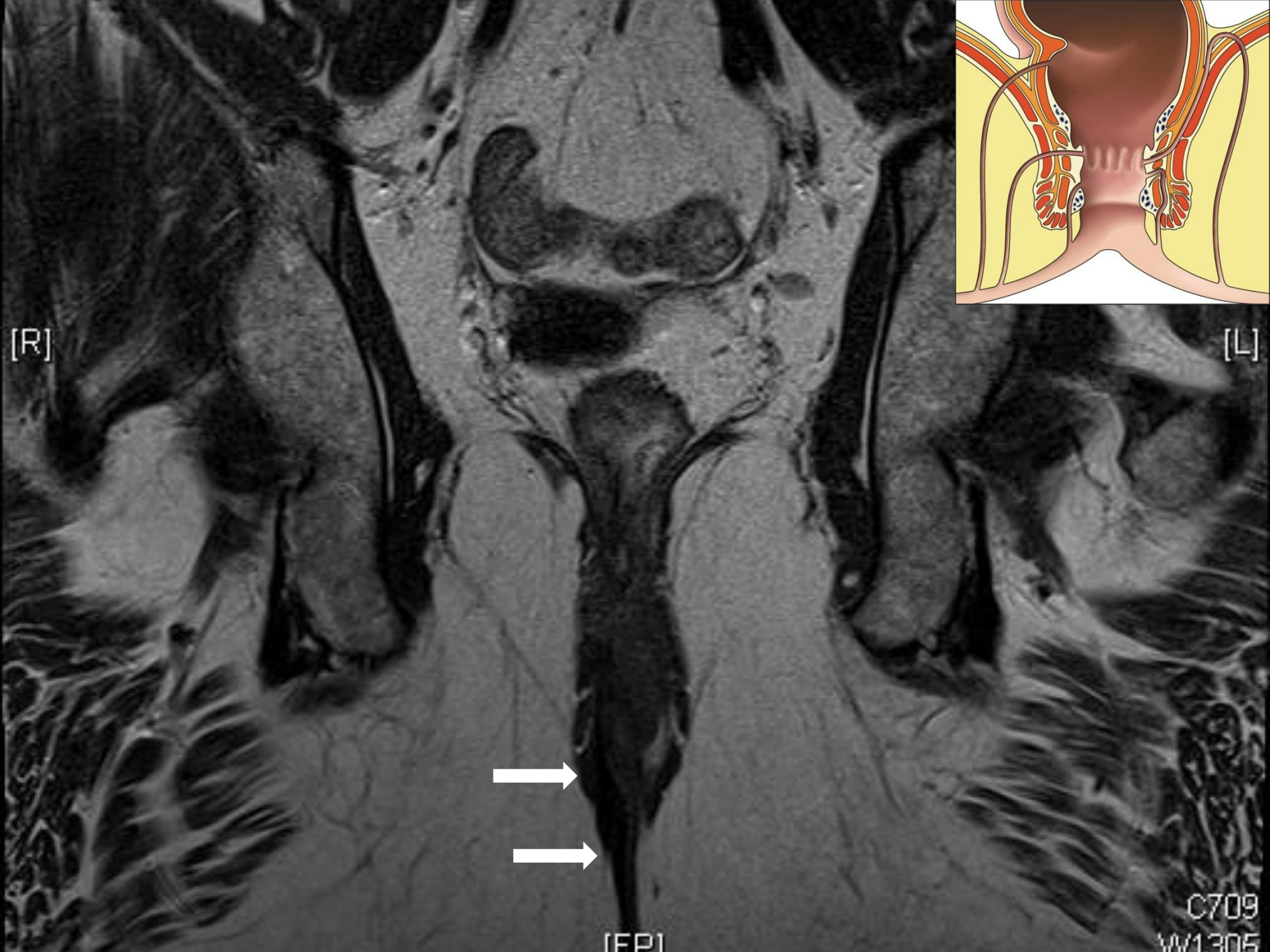[R]

[L]



[FPI]

C709  
W1305



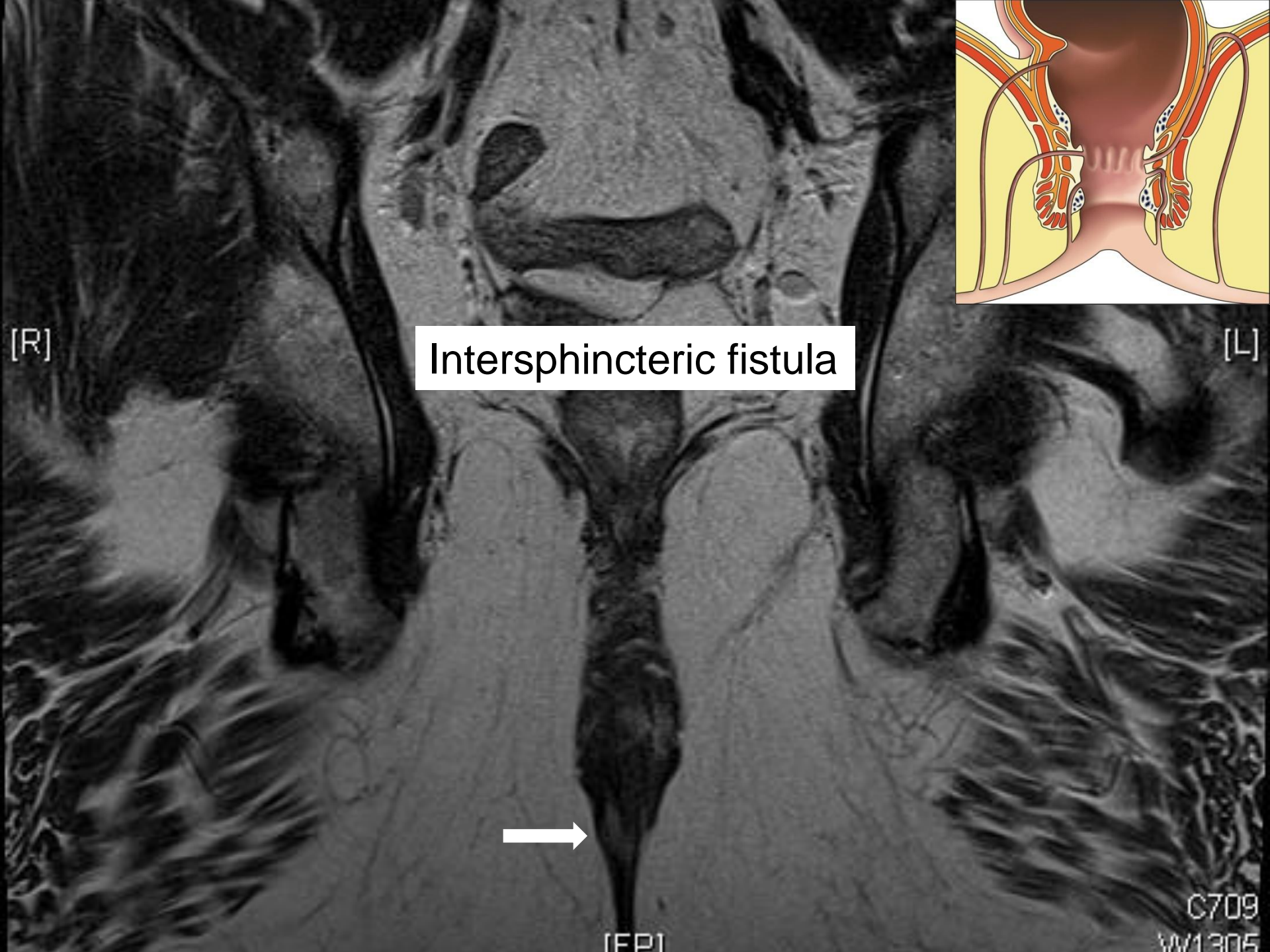
[R]

[L]

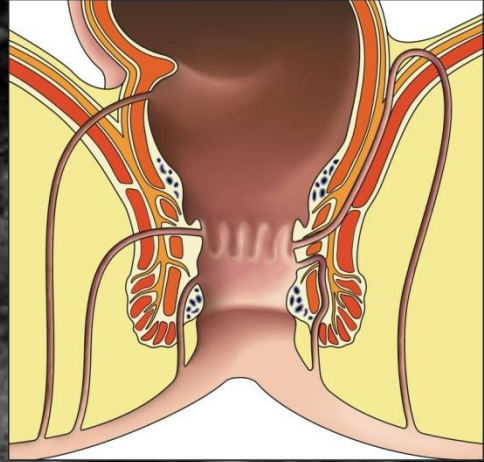


[FPI]

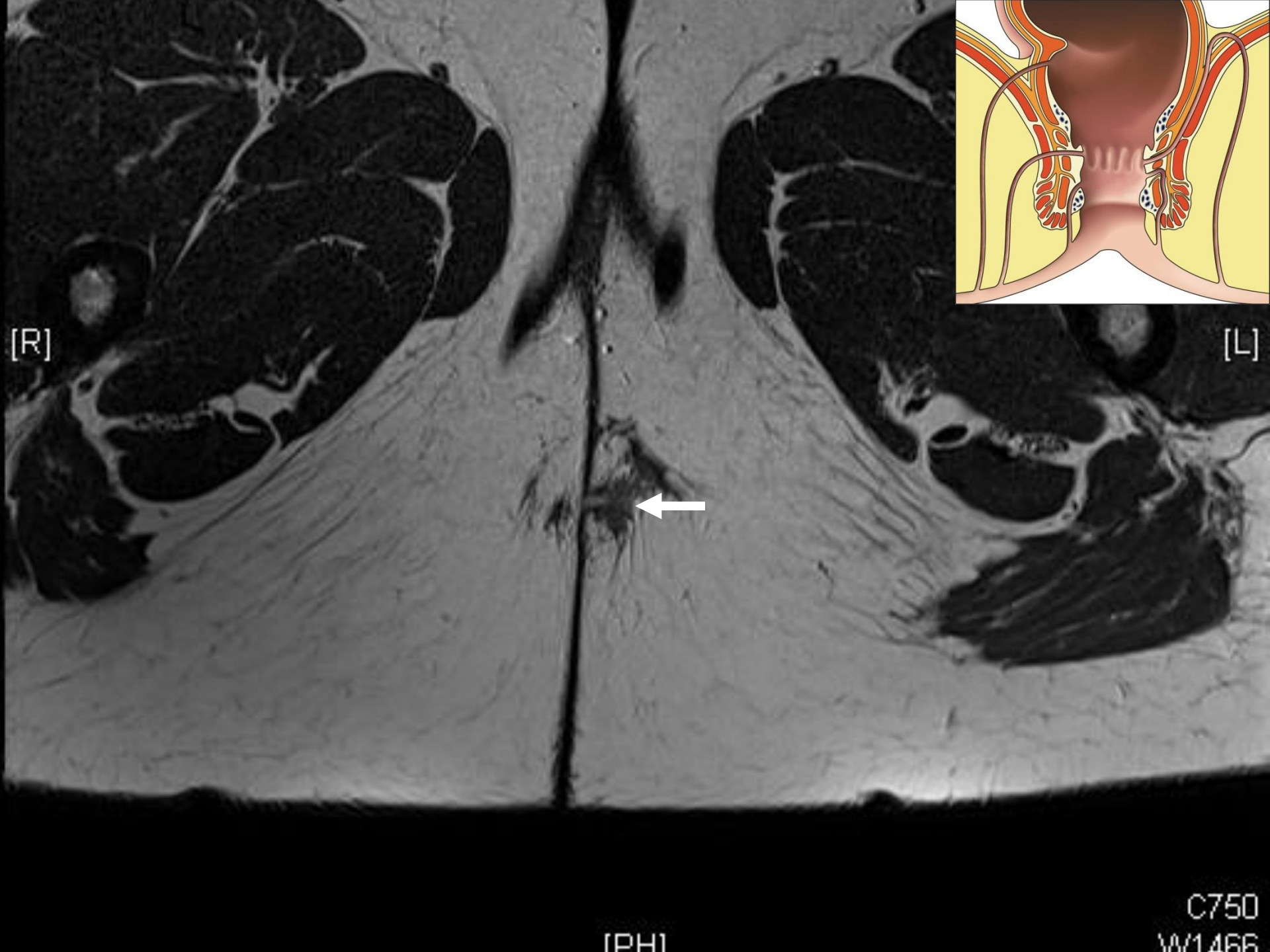
C709  
W1305



Intersphincteric fistula



# *Case 2*



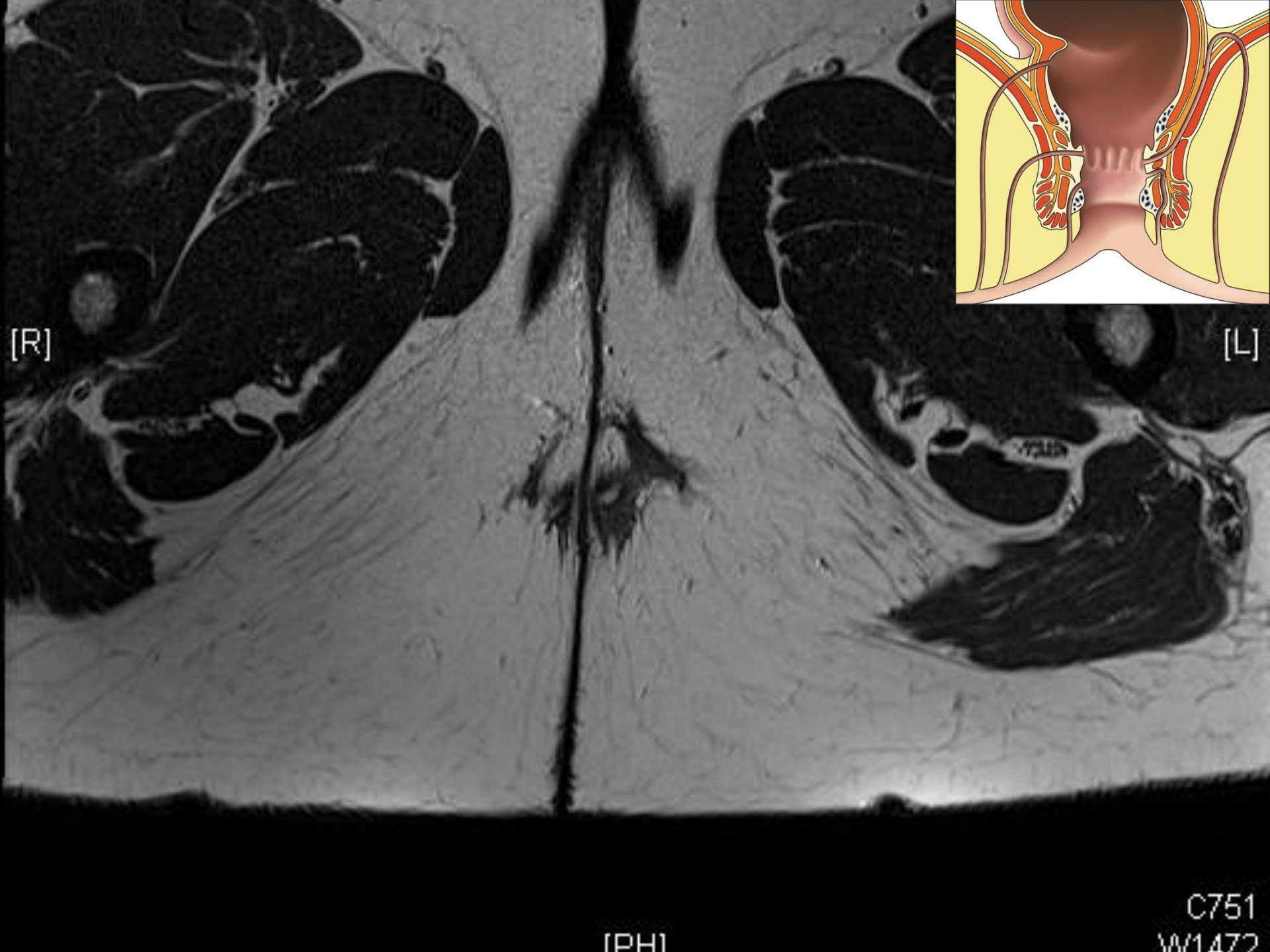
[R]

[L]

[PH]

C750  
W1466



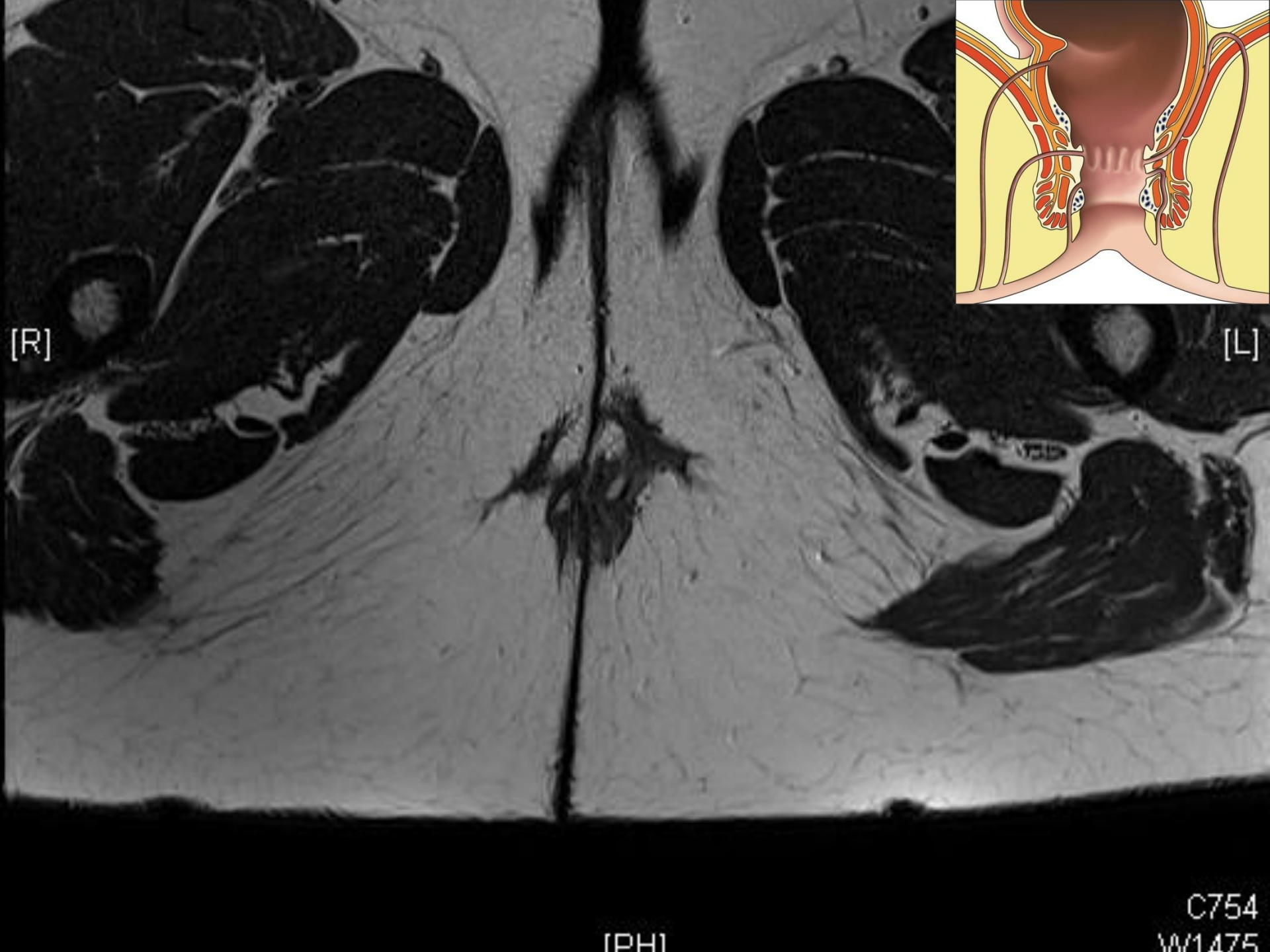


[R]

[L]

[PH]

C751  
W1472

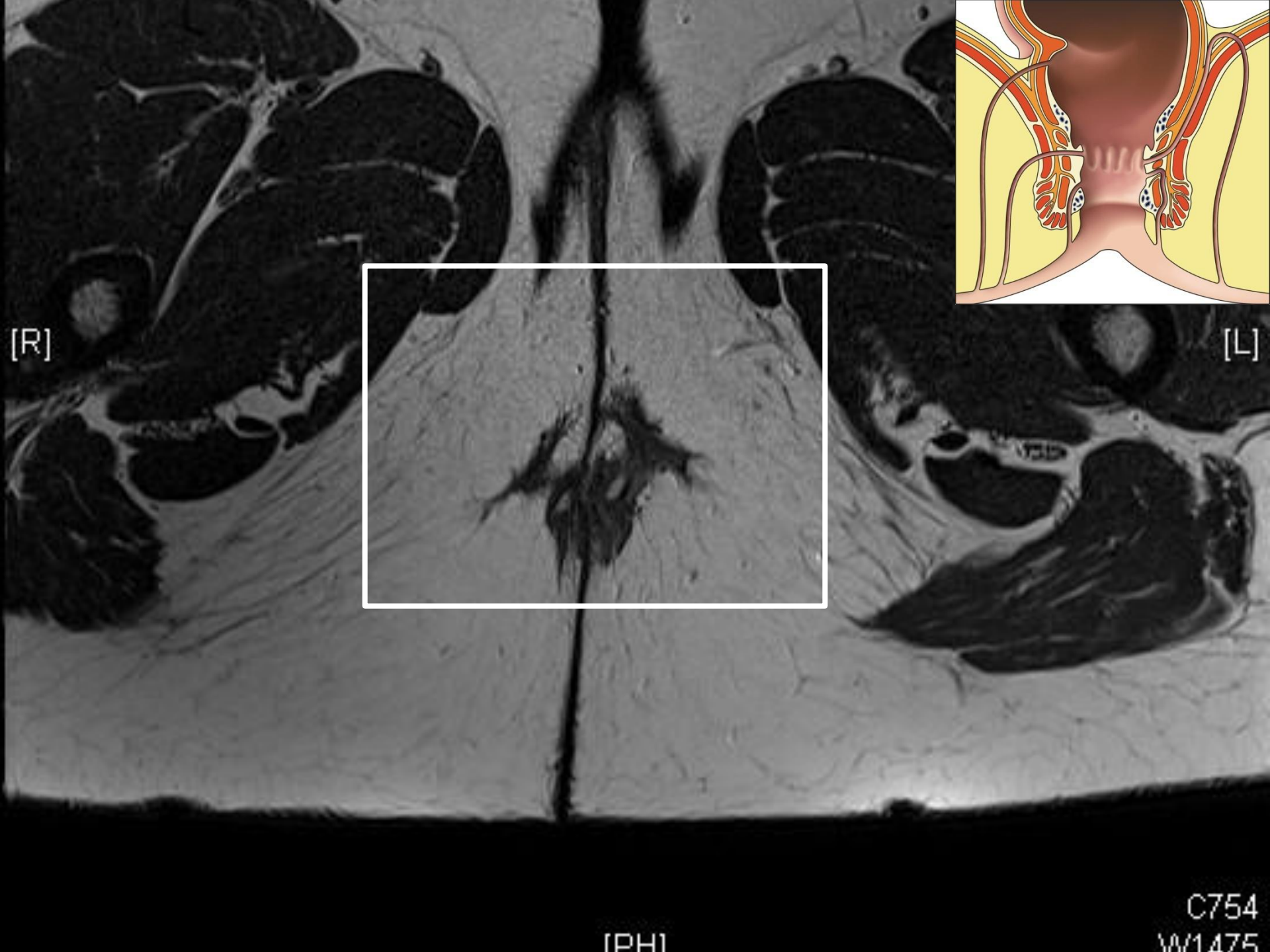


[R]

[L]

[PH]

C754  
W1475

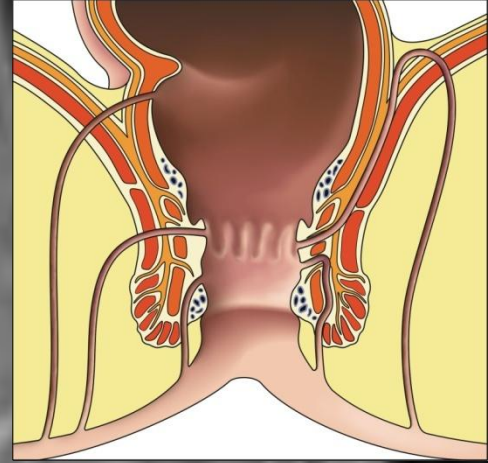
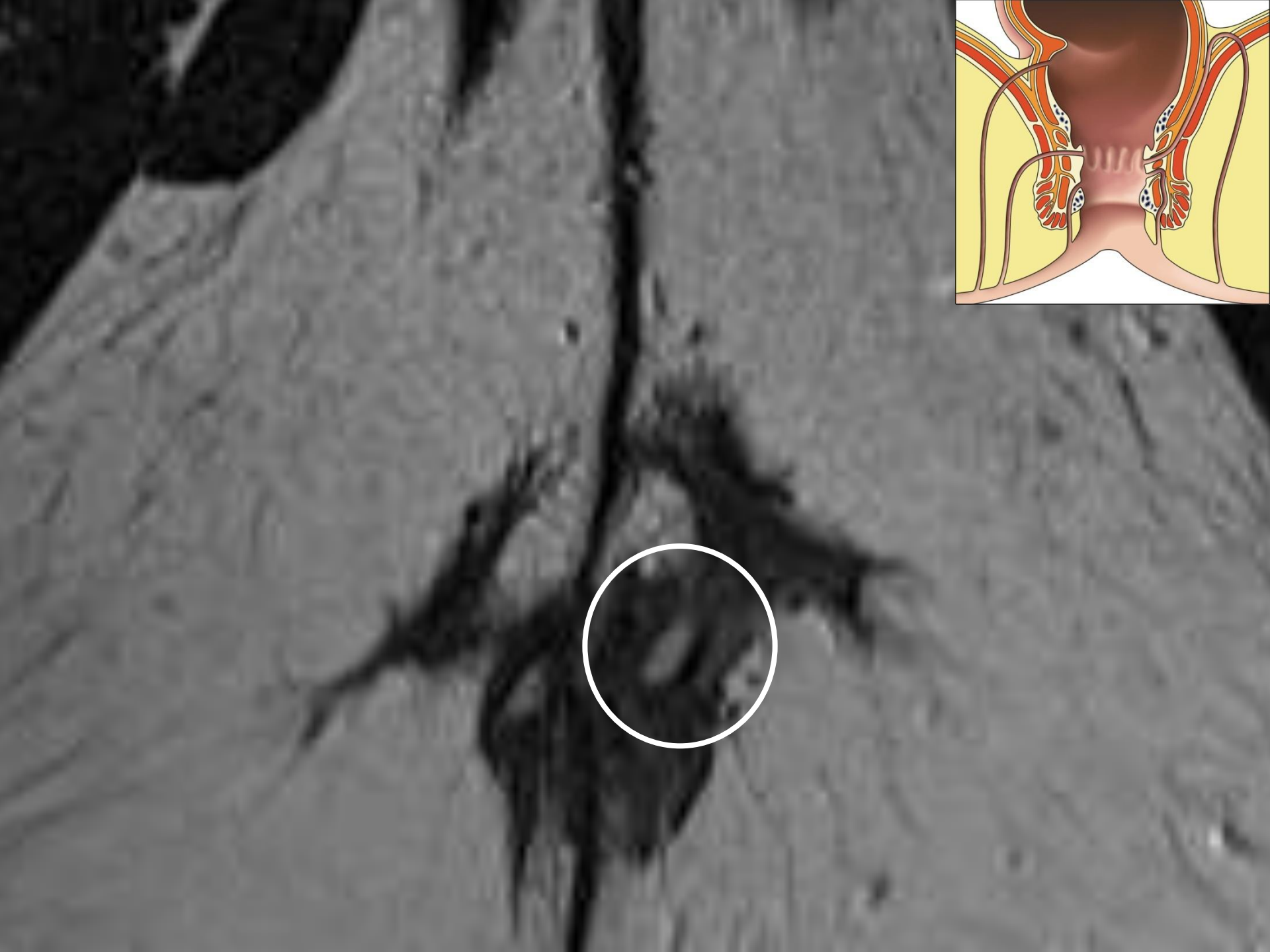

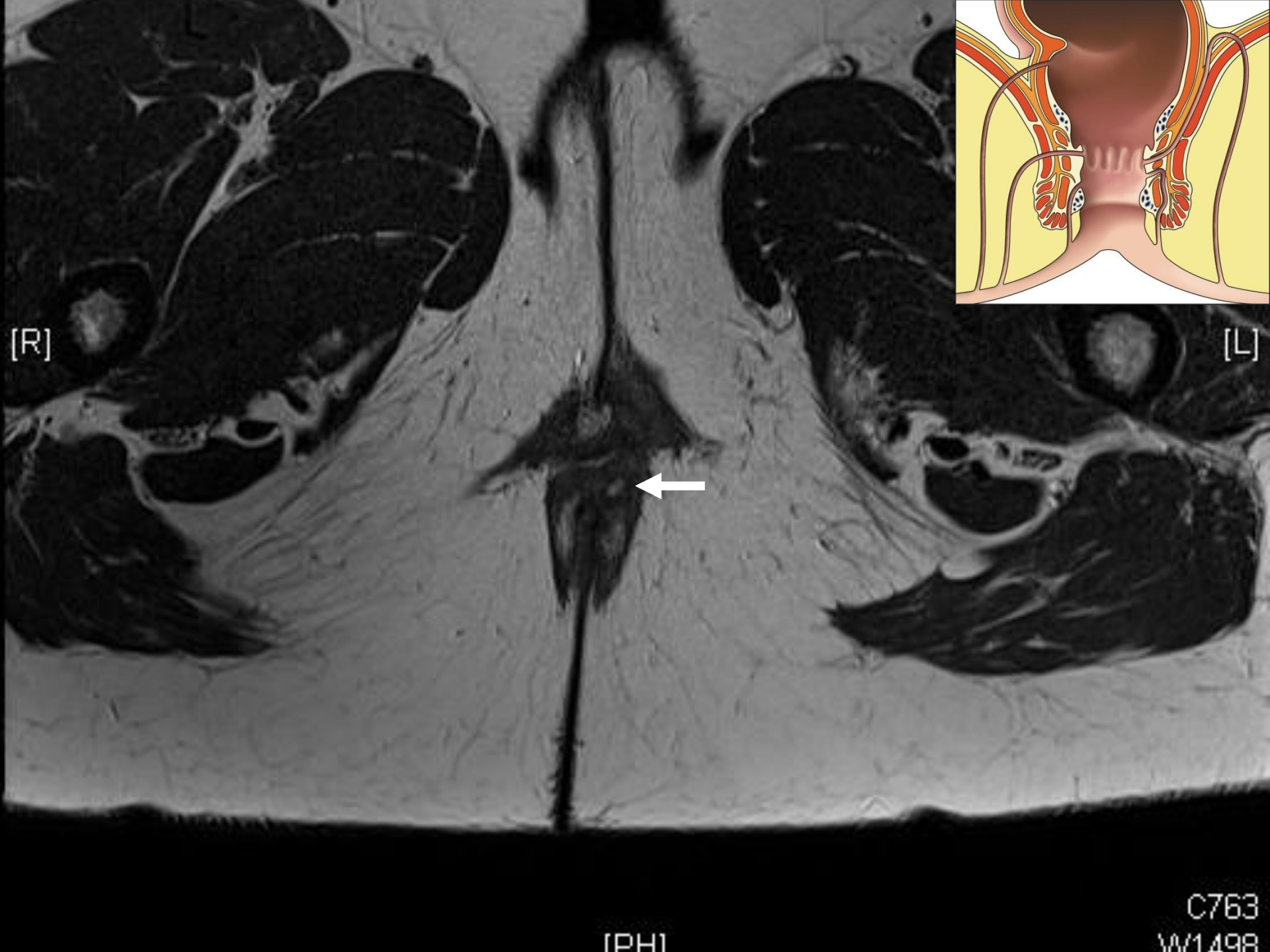
[R]

[L]

[PH]

C754  
W1475



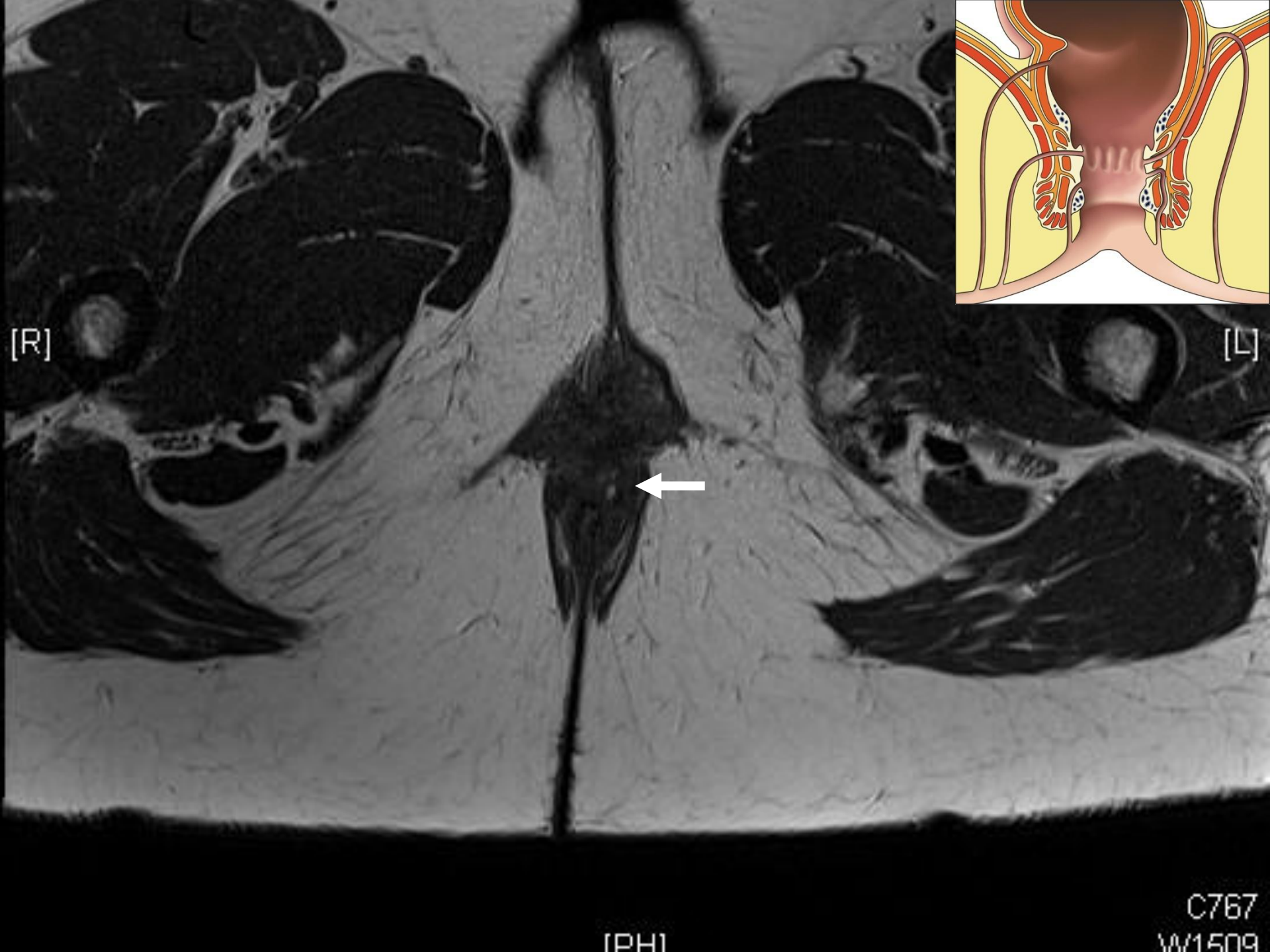


[R]

[L]

[PH]

C763  
W1498

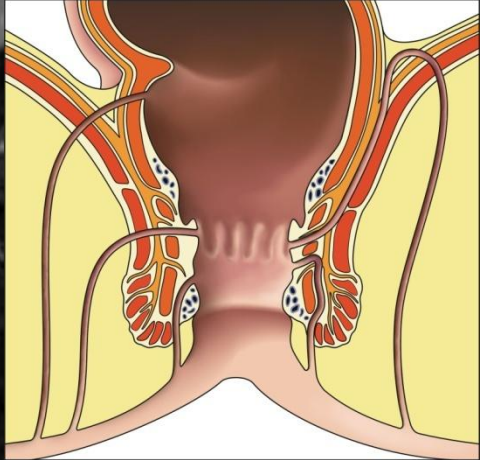
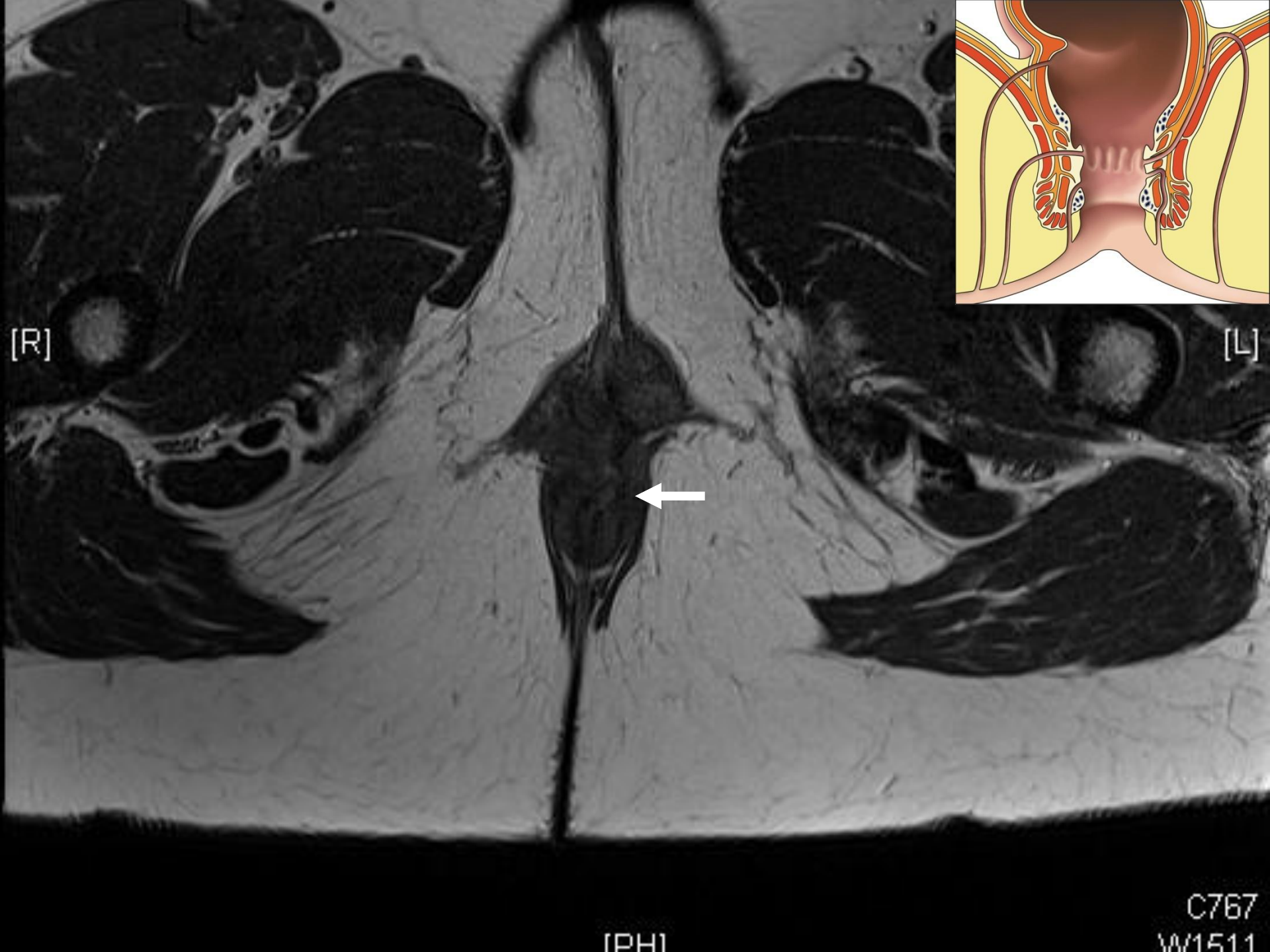

[R]

[L]

[PH]

C767  
W1509



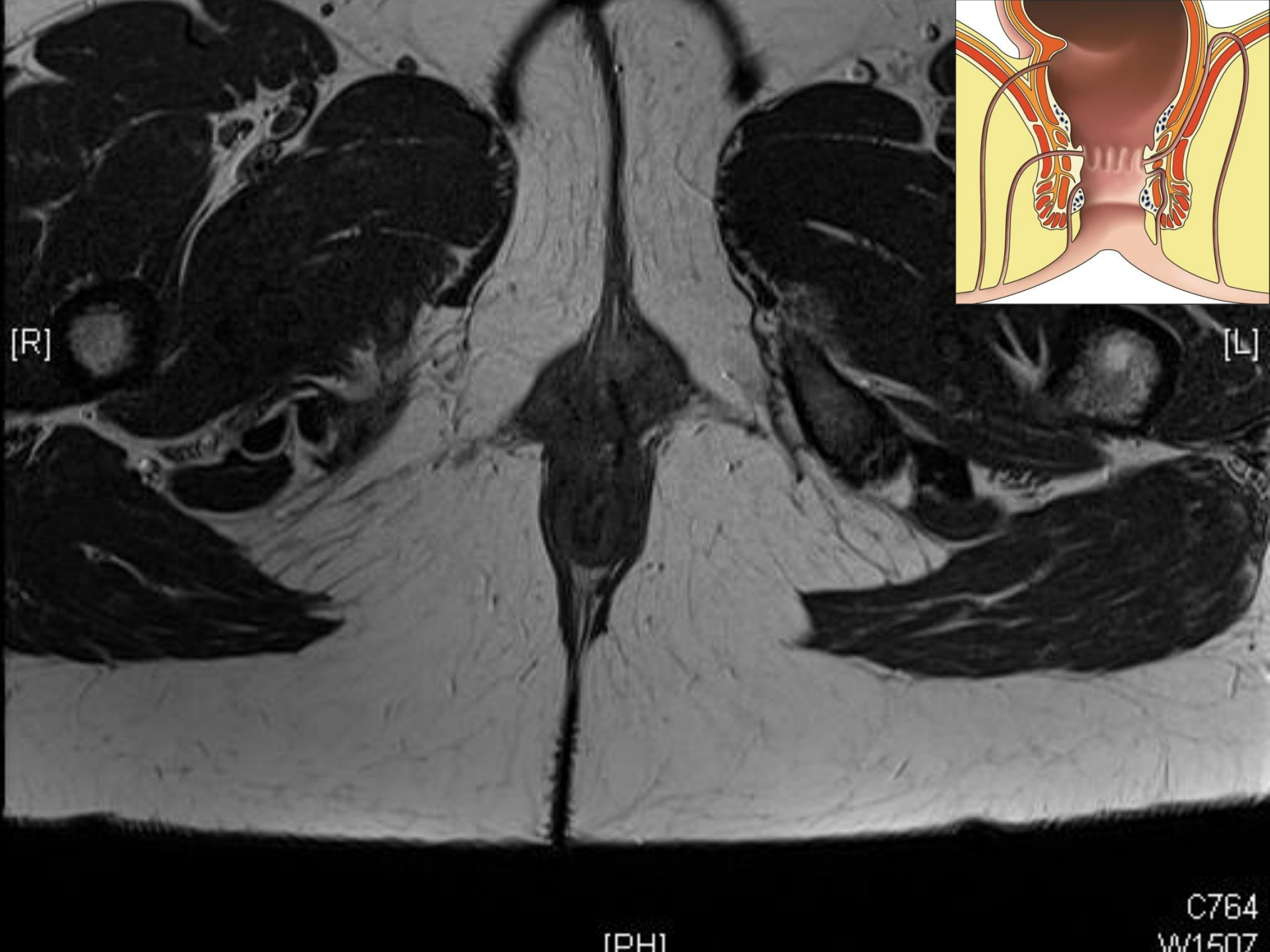
[R]

[L]



[PH]

C767  
W1511



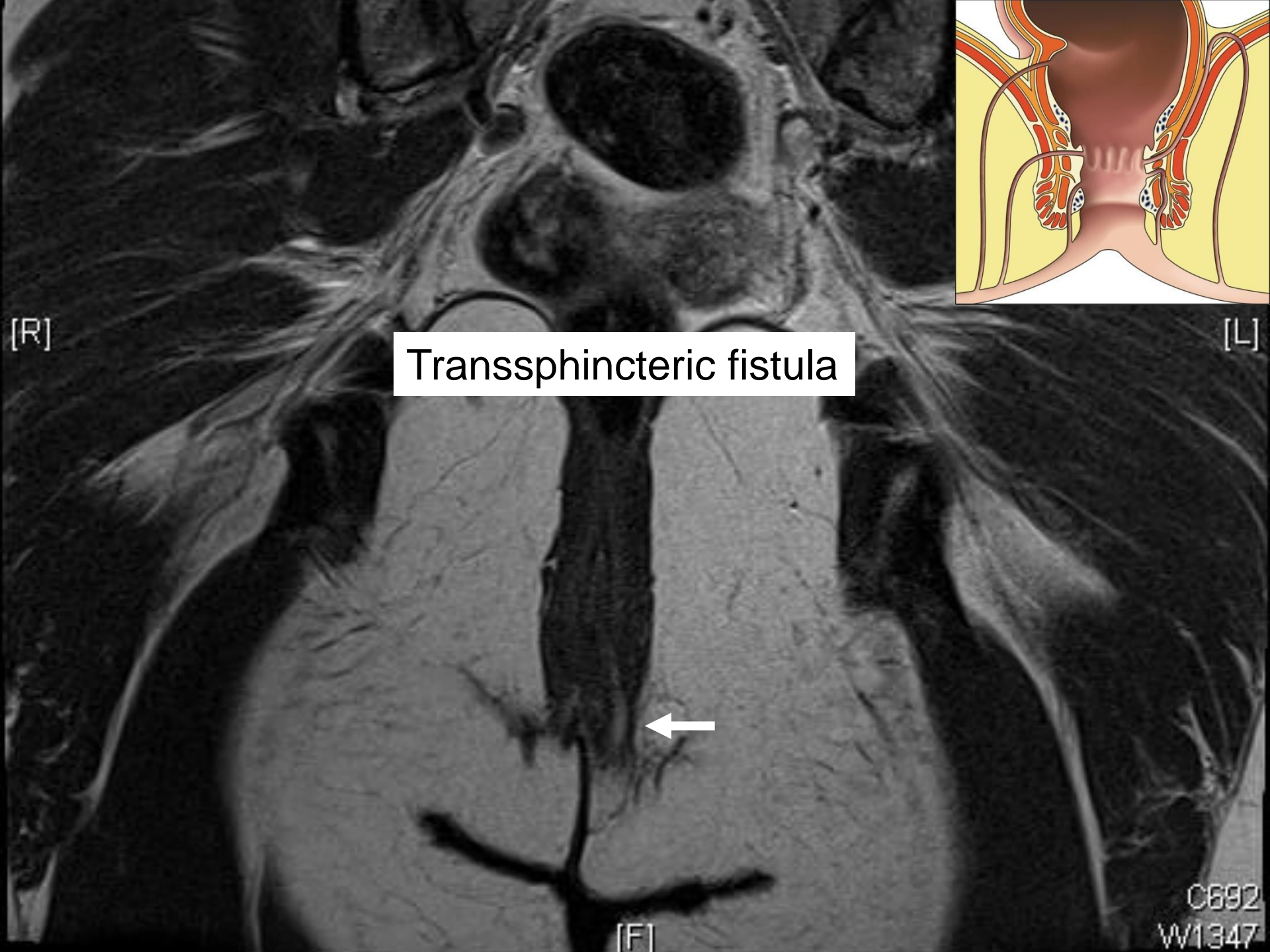
[R]

[L]

[PH]

C764  
W1507



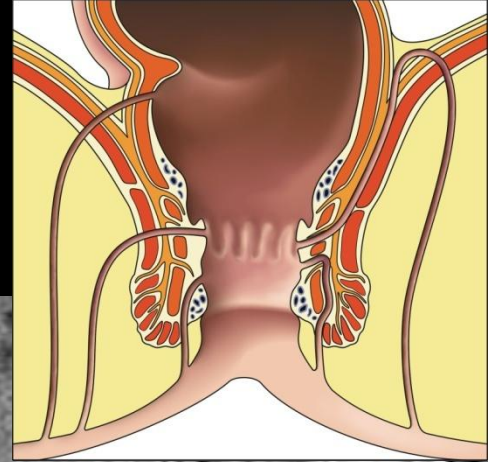
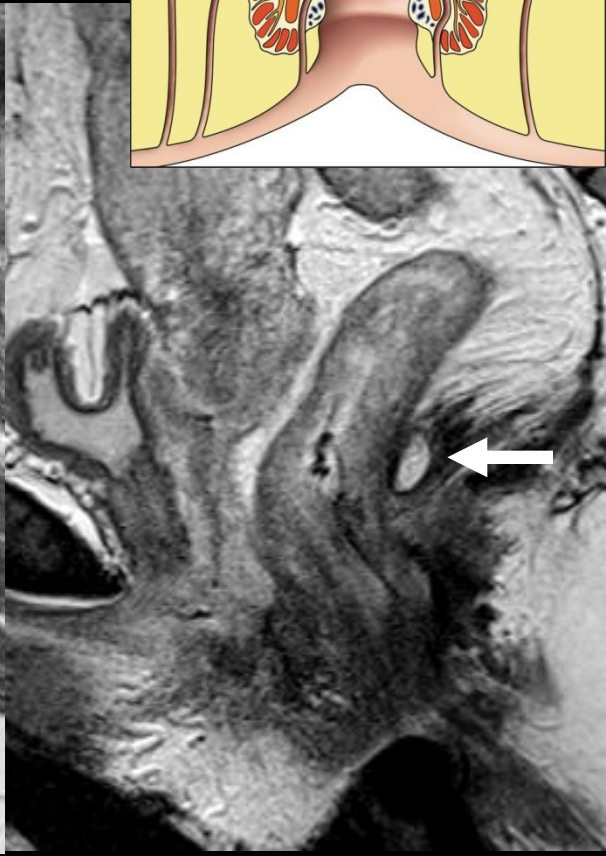
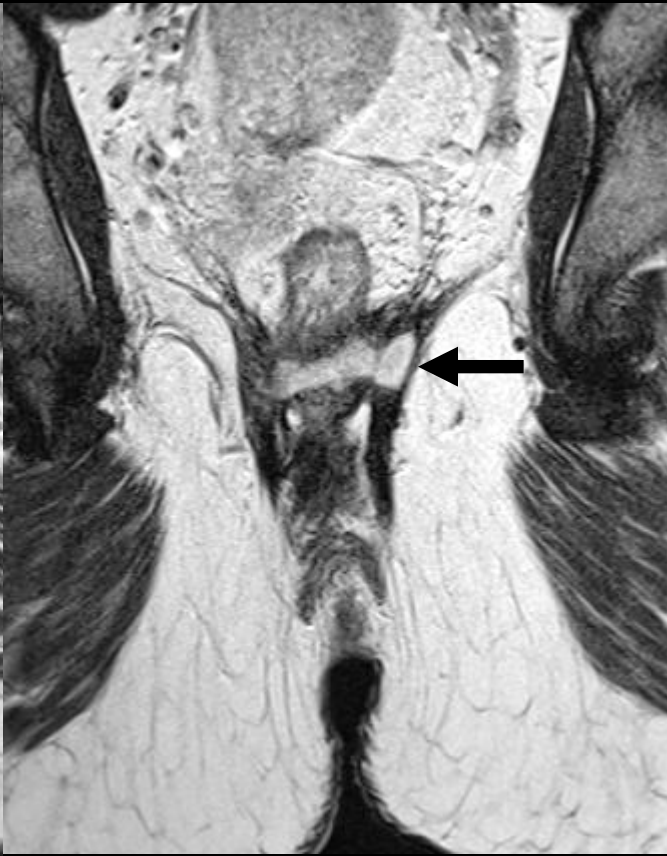
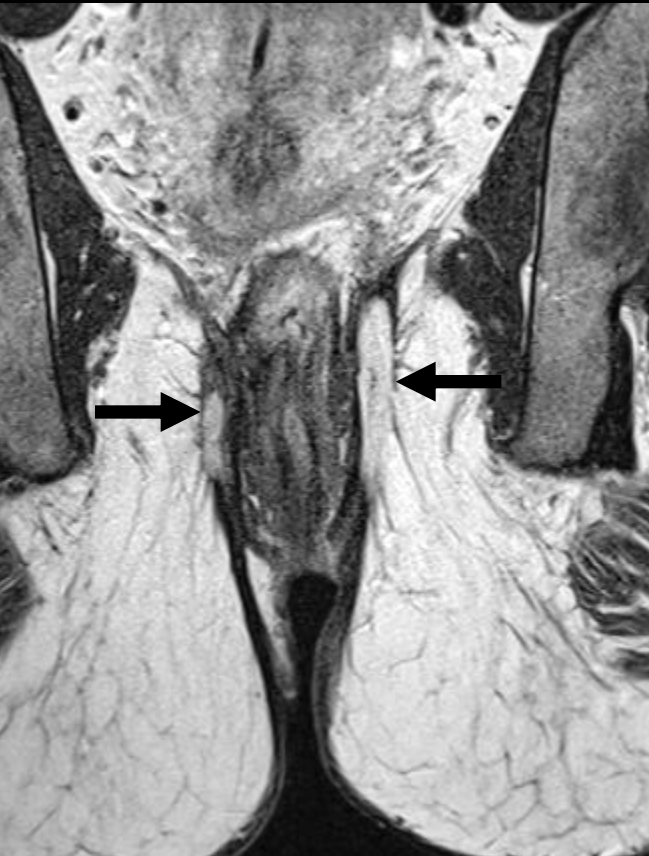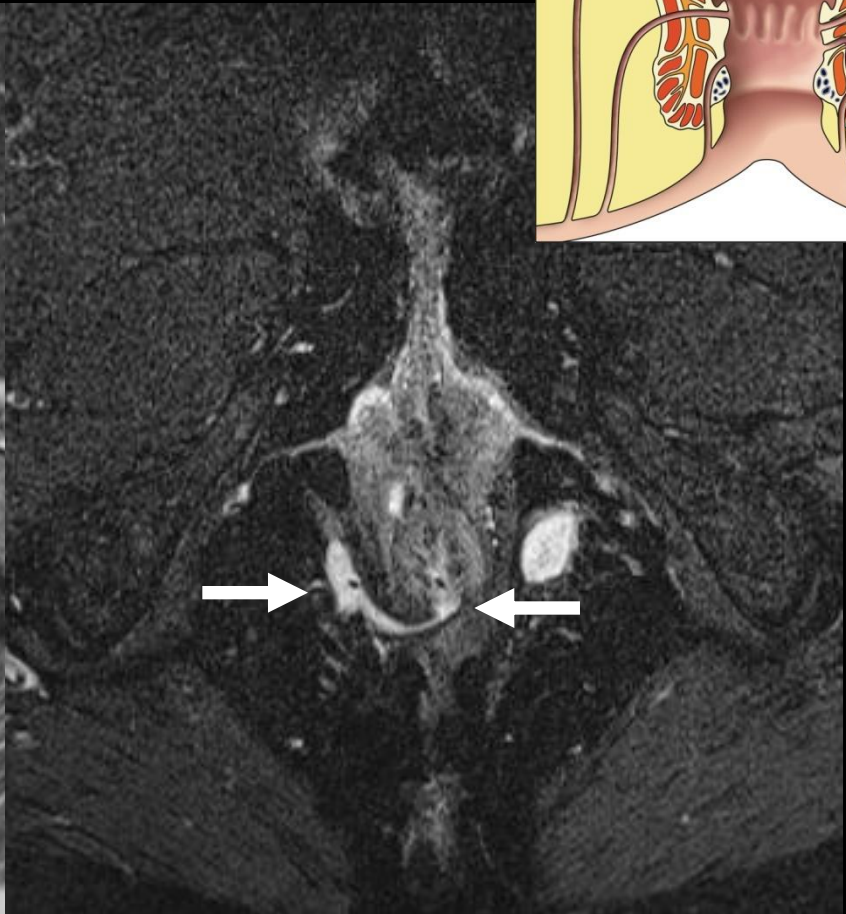
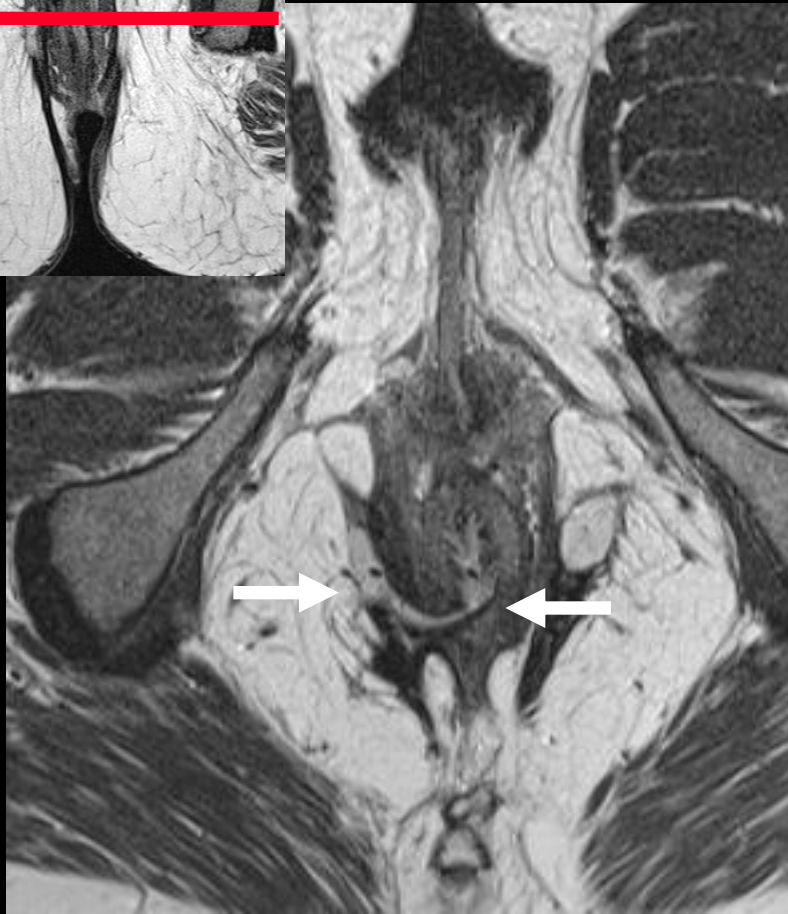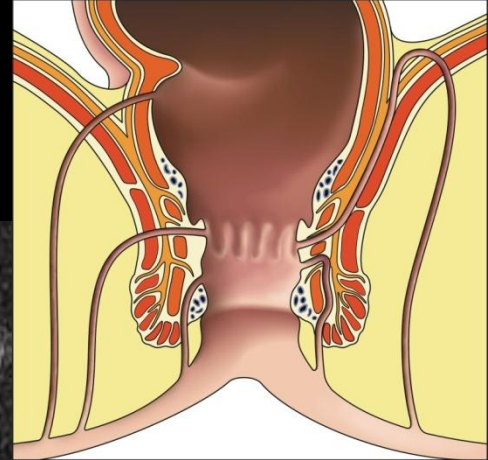
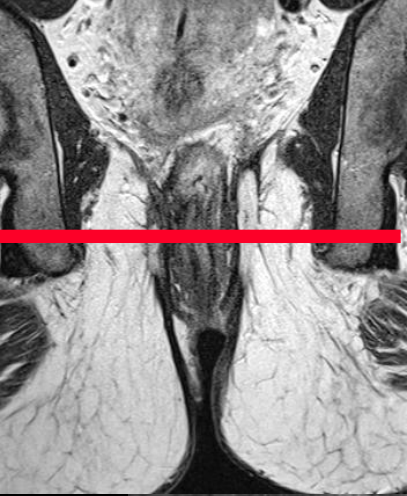
Transsphincteric fistula



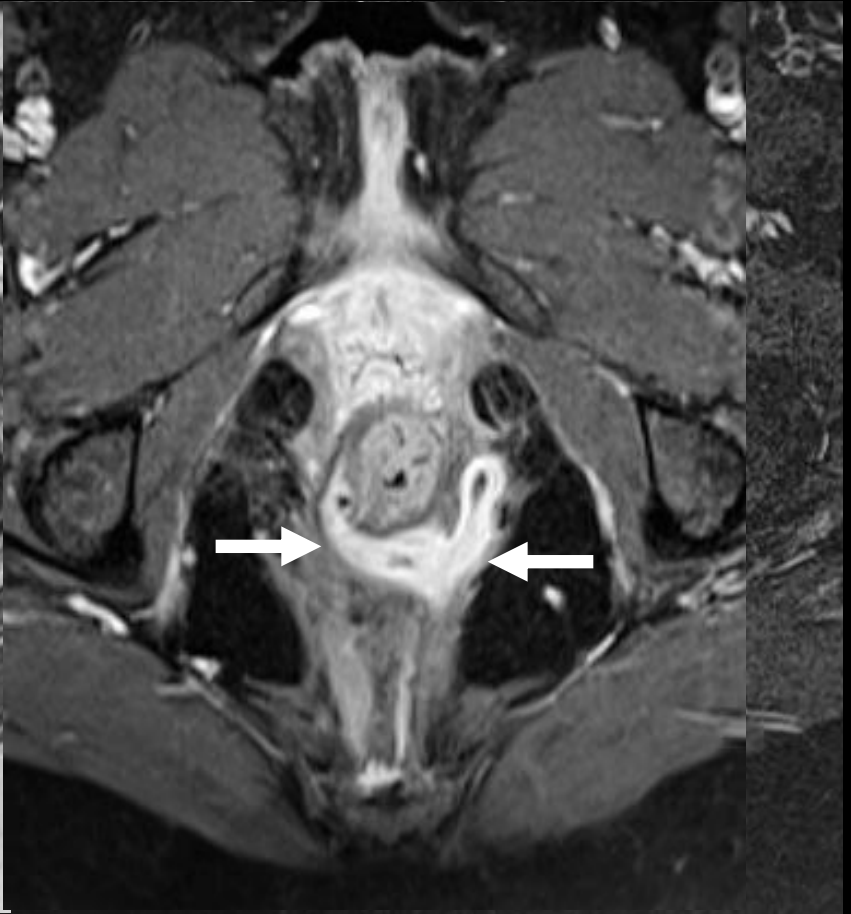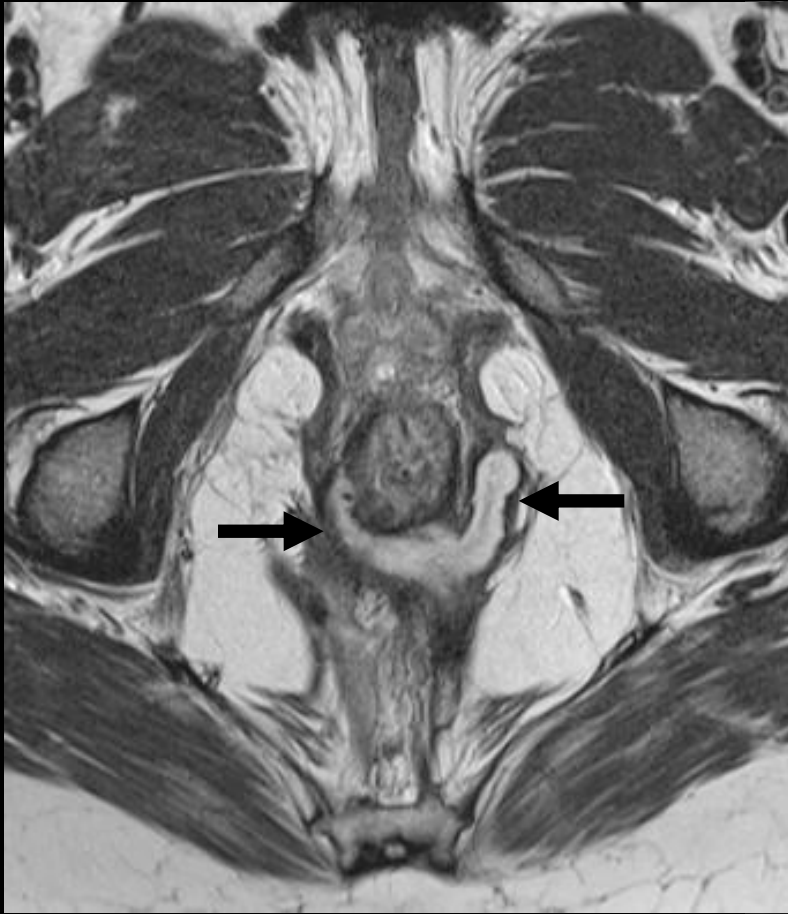C692  
W1347

# *Case 3*

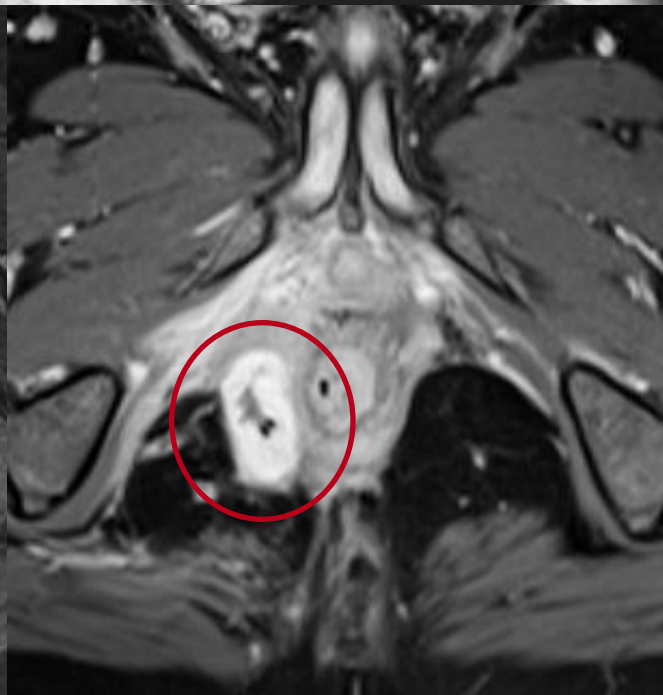
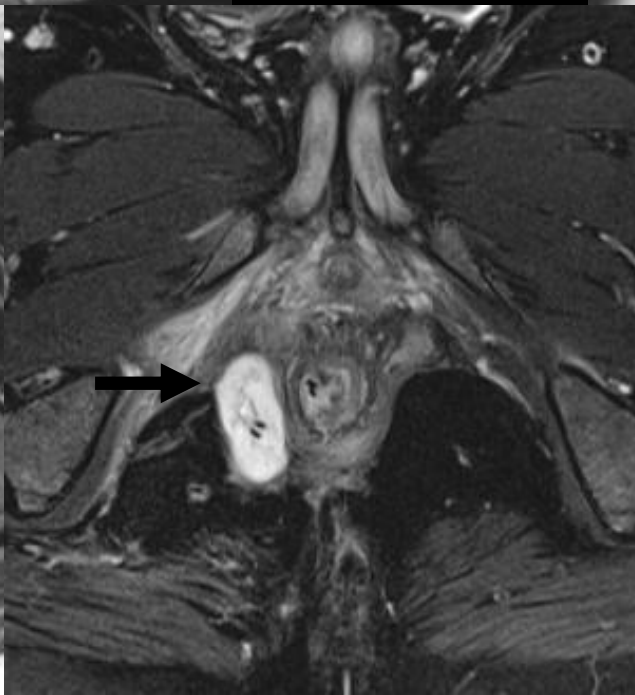
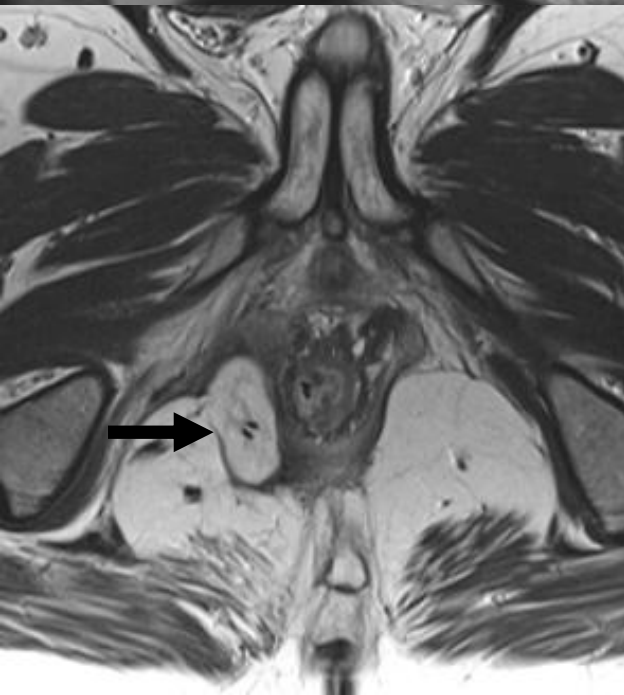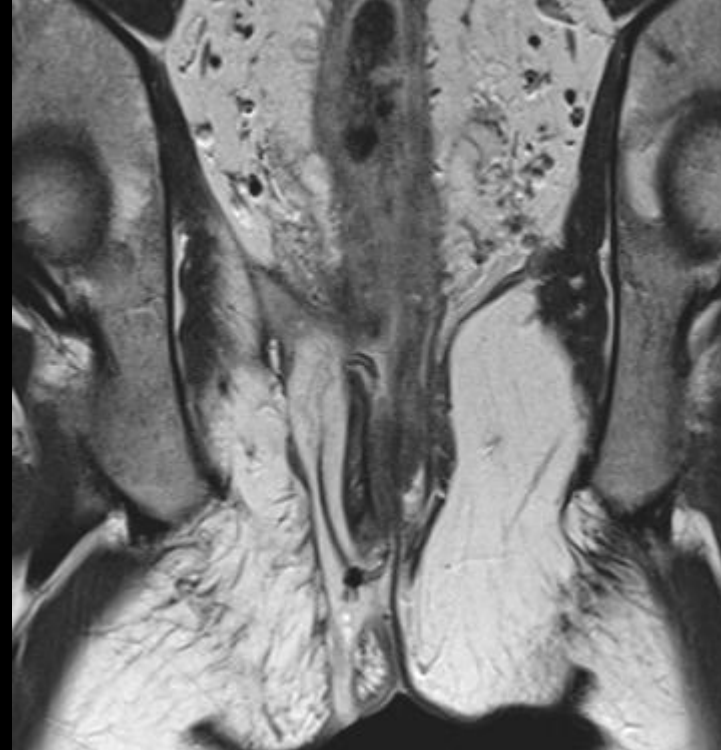
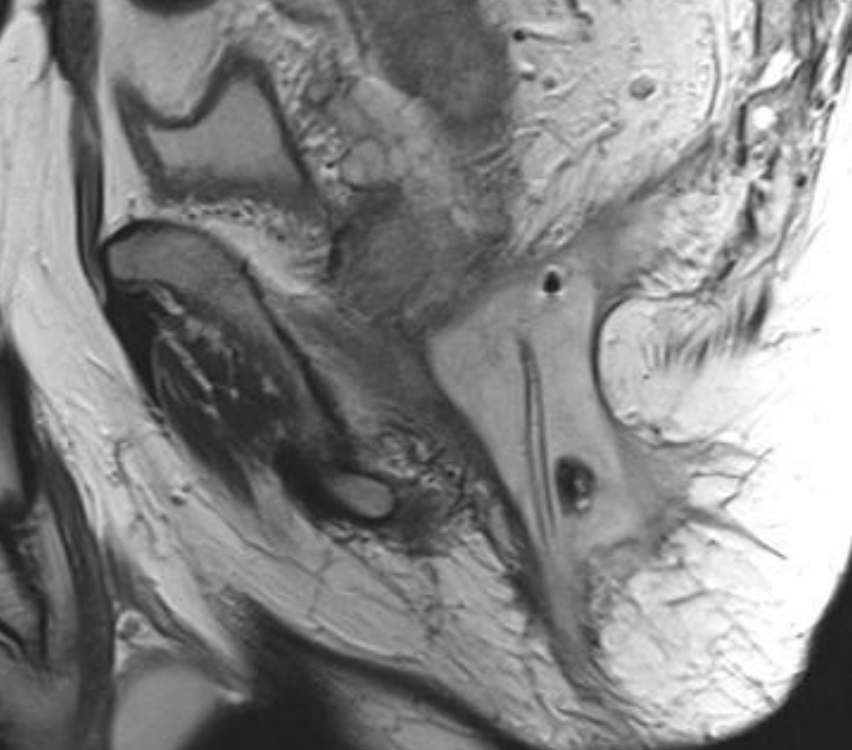




Transsphincteric fistula with intralevator extent

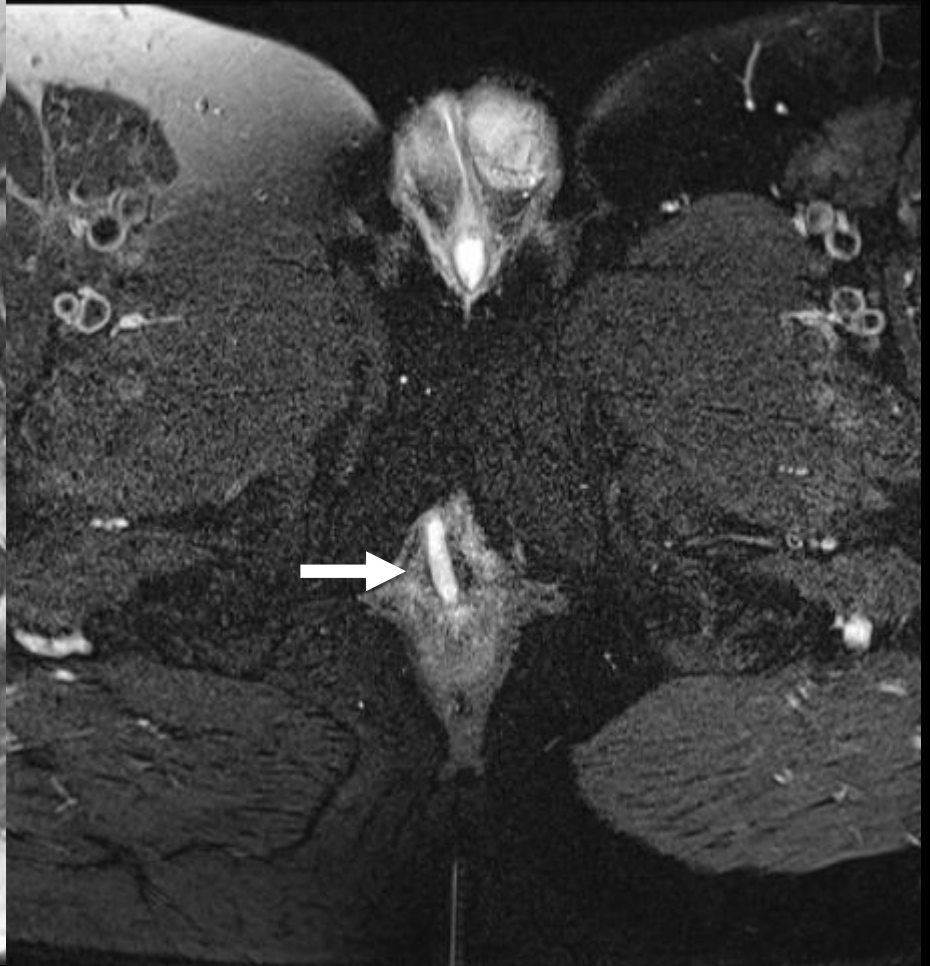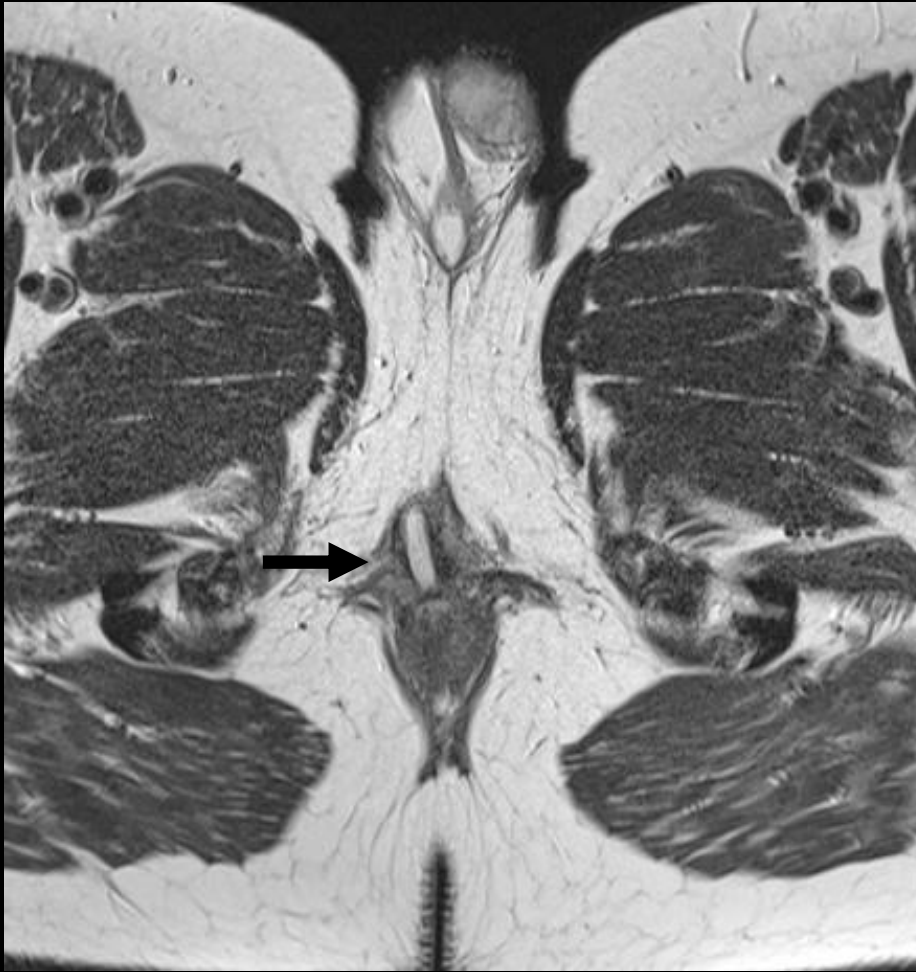


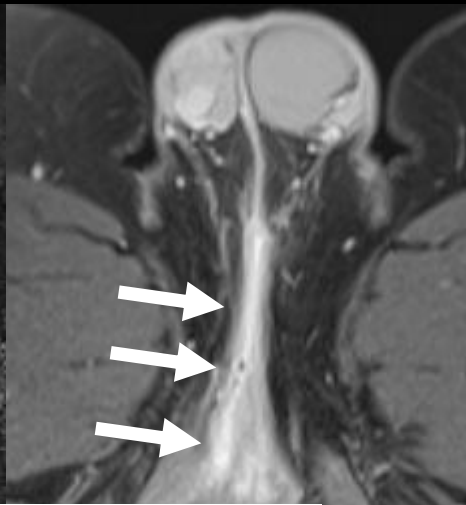
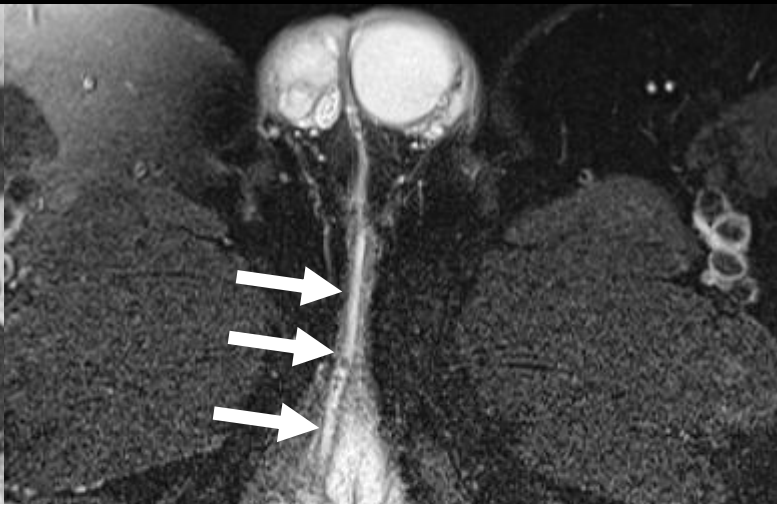
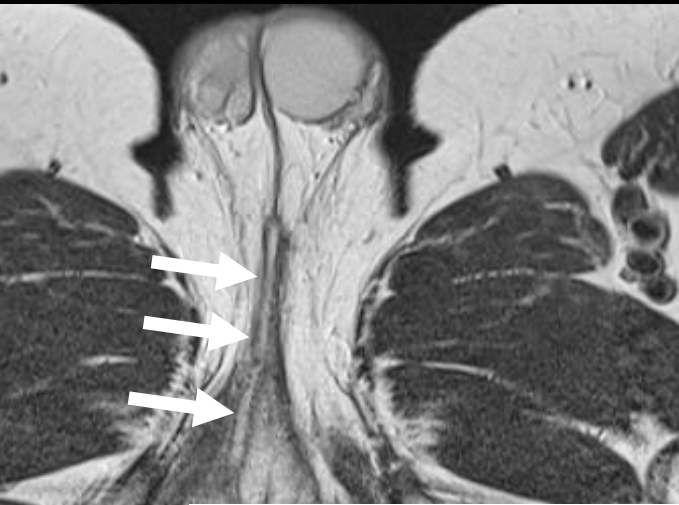# *Case 4*



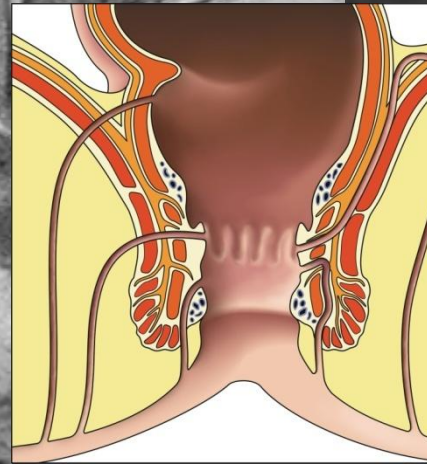
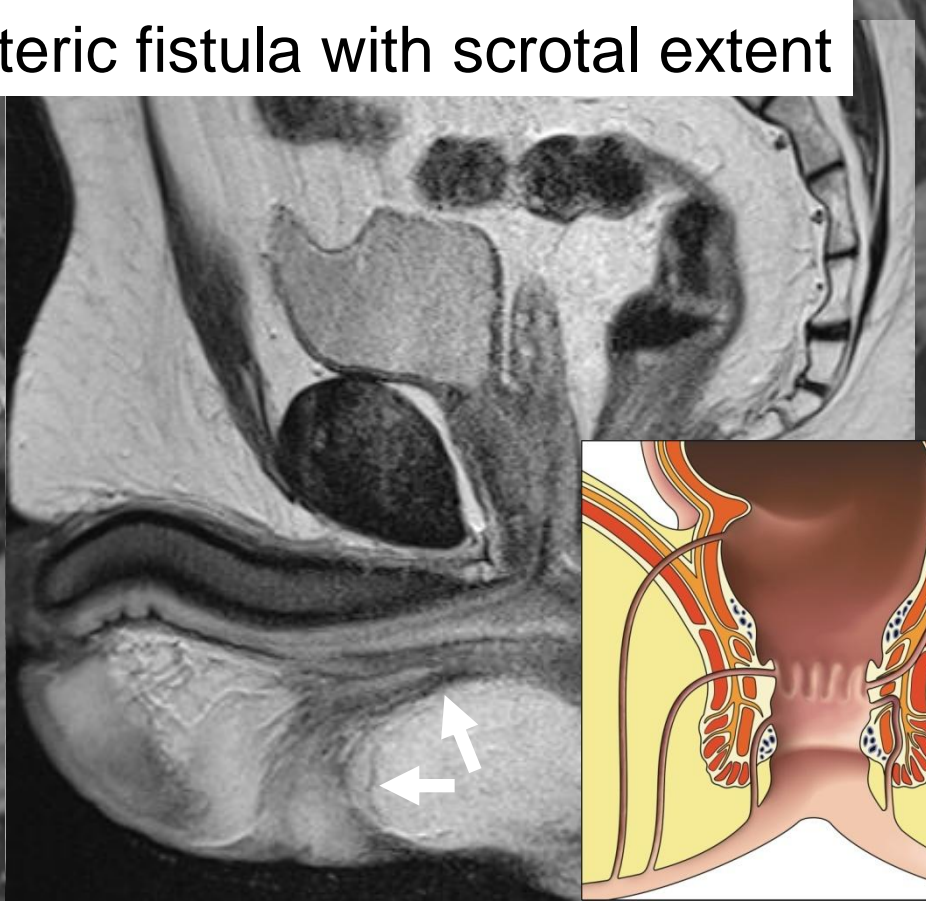
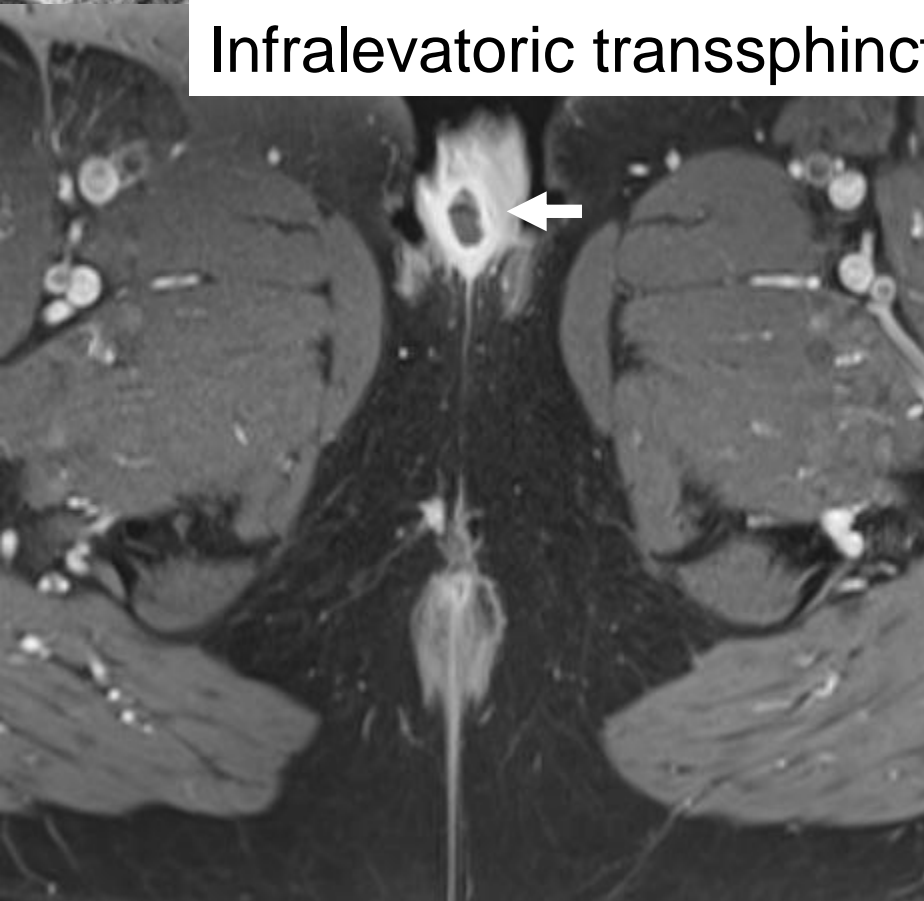
# *Case 5*



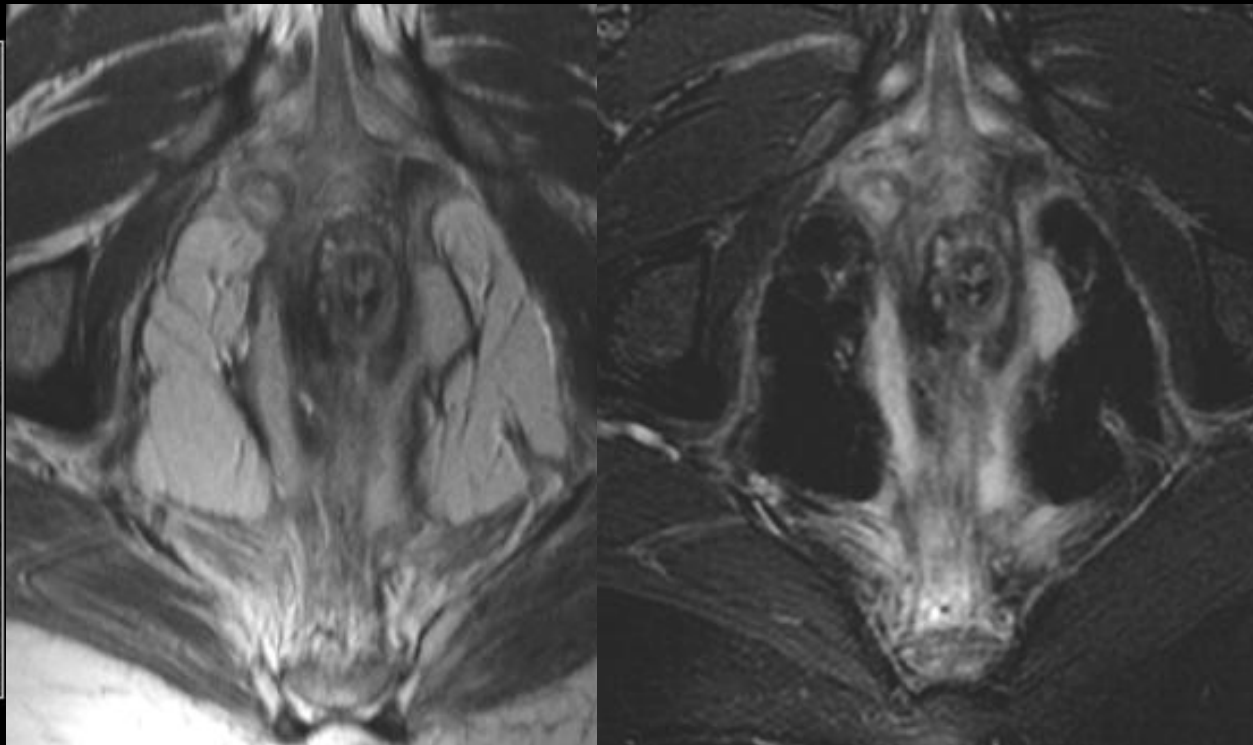
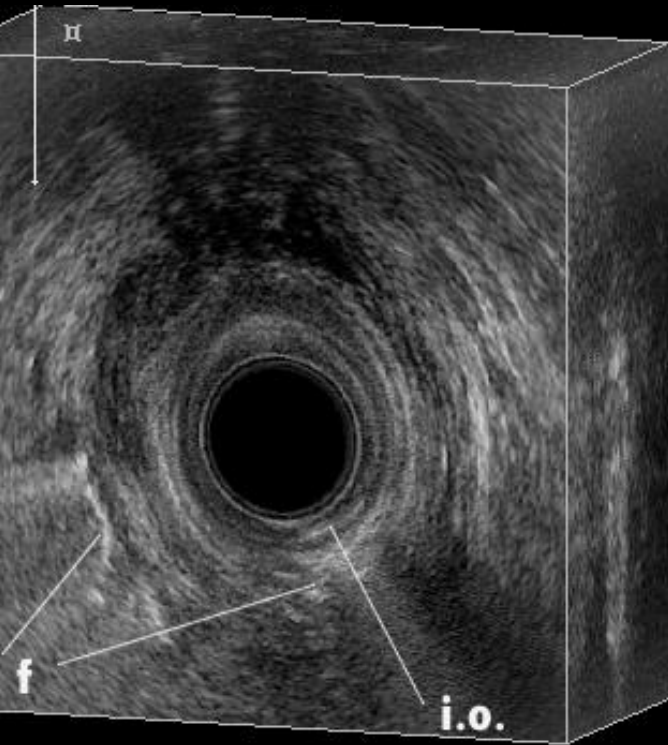




Infralevatoric transsphincteric fistula with scrotal extent



# *EUS vs. MRI*



Low, simple tracks  
Complex tracks  
High tracks  
Internal opening

EUS=MRI  
EUS<MRI  
EUS<MRI  
EUS>MRI

# *Take home messages*

- *MRI mainstay in perianal fistulas*
  - *Detection, Classification, Monitoring*
  - *Improves outcome in recurrent disease and complex disease (CD)*
- *External MRI*
- *i.v. contrast in CD*

- *Dank voor uw aandacht*

- *Prof. dr. Jaap Stoker (AMC)*